

Cutaneous Horn with Underlying Squamous Cell Carcinoma of Lower Lip

¹JS Jesija, ²Saurabh Kumar, ³Rebecca Paul, ⁴Rabin Chacko, ⁵Mayur Suryawanshi

ABSTRACT

Context: Cornu cutaneum associated with squamous cell carcinoma is a relatively unusual presentation in lower lip. Cutaneous horn may be associated with benign, premalignant, or malignant cutaneous lesions and is characterized by the presence of abnormal keratinized material. Here we present a 63-year-old female patient with a cutaneous horn in lower lip with underlying squamous cell carcinoma of left buccal mucosa.

Aims: This case report aims to draw attention to the fact that cutaneous horn can occur very rarely in association with malignancy.

Materials and methods: Tissue was fixed in 10% formalin; 0.3 µm thick sections were obtained from paraffin-embedded tissues, stained with routine hematoxylin and eosin stains, and then reviewed.

Conclusion: Examination of hematoxylin and eosin stained sections showed fibrocollagenous tissue lined by hyperkeratinized, dysplastic stratified squamous epithelium, with subepithelial foci of dysplastic squamous cells, suggestive of carcinoma *in situ* with suspicion of early invasive squamous cell carcinoma.

Keywords: Cornu cutaneum, Cutaneous horn, Lower lip, Squamous cell carcinoma.

How to cite this article: Jesija JS, Kumar S, Paul R, Chacko R, Suryawanshi M. Cutaneous Horn with Underlying Squamous Cell Carcinoma of Lower Lip. Oral Maxillofac Pathol J 2016;7(2):726-729.

Source of support: Nil

Conflict of interest: None

INTRODUCTION

Cutaneous horn is a conical hyperkeratotic projection above the surface of the skin that often resembles the horn of an animal. It is a relatively unusual lesion, also known as "cornu cutaneum" in Latin. It may be straight, curved, or twisted and may vary from a few millimeters to several centimeters in length.^{1,2} Most often, cutaneous horns occur in sites that are exposed to actinic radiation or burns and,

therefore, are typically found on upper parts of the face. In addition, 60% of the lesions are benign; however, malignant or premalignant lesions might be associated with these lesions.³ Cutaneous horn occurs very infrequently in association with malignancy.⁴ This is a case report of a cutaneous horn in lower lip with underlying squamous cell carcinoma of left buccal mucosa in a 63-year-old female.

CASE REPORT

A 63-year-old lady presented with a complaint of growth in the left corner of the lip for the past 3 years. History revealed that it started as a small peanut size growth that gradually enlarged in size and formed projections on the corner of the lip. She had a habit of chewing tobacco for the past 20 years, which she had quit completely 2 years back. Her medical history revealed that she was a patient of diabetes and hypertension for which she was on medication.

On examination, two horn-like projections of keratinized tissue were seen in the left lip commissure parallel to each other (Fig. 1). The horn that was seen in the above inset in Figure 1 was 1 cm in length and the one below was larger and 3 cm in length. The surface appeared rough and blackened, and hairs were noticed on their surface (Fig. 2). The base was sessile and hyperkeratotic and the surrounding mucosa posterior to the horns appeared proliferated. A diffuse white patch was noted extending posteriorly from the commissure of the lip to the buccal mucosa and inferiorly toward the corresponding buccal vestibule.

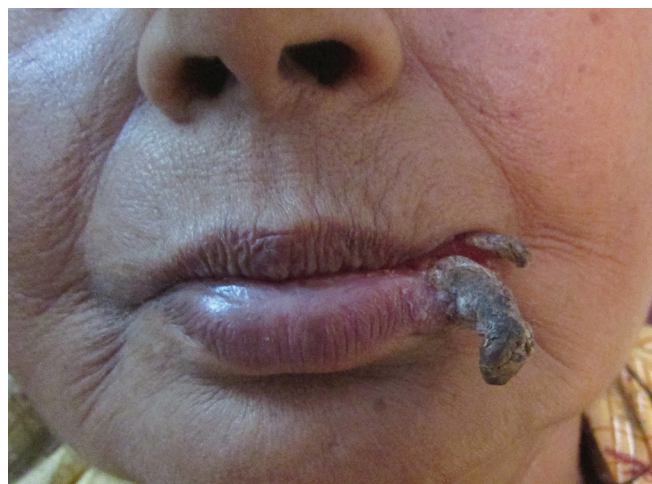

Fig. 1: Two horn-like projections in the lower lip

^{1,2,5}Assistant Professor, ³Trainee, ⁴Professor

¹⁻⁴Department of Dental and Oral Surgery, Christian Medical College & Hospital, Vellore, Tamil Nadu, India

⁵Department of Pathology, Christian Medical College & Hospital Vellore, Tamil Nadu, India

Corresponding Author: JS Jesija, Assistant Professor, Department of Dental and Oral Surgery, Christian Medical College & Hospital Vellore, Tamil Nadu, India, e-mail: jesijafinlay@gmail.com

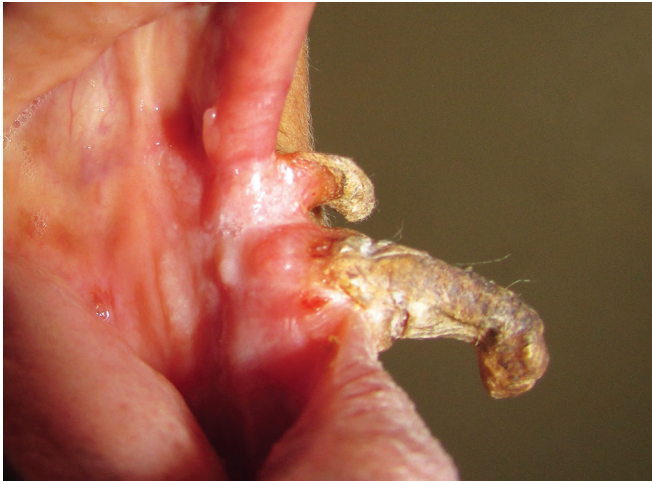

Fig. 2: The surface appeared blackened, rough, and hairs were noticed in its surface

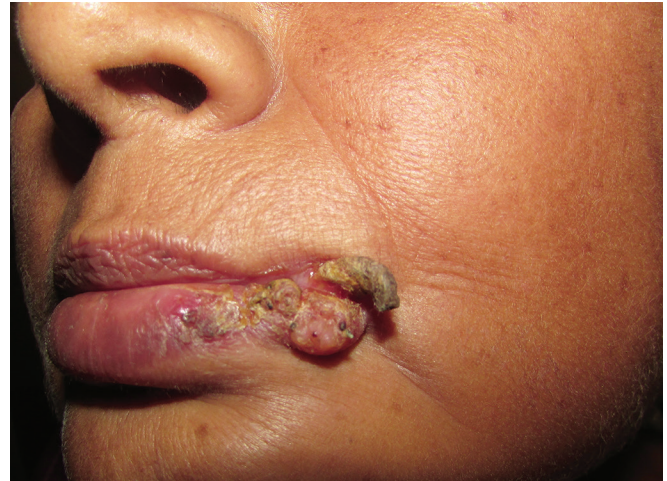

Fig. 3: Cutaneous horn exfoliated on its own without provocation

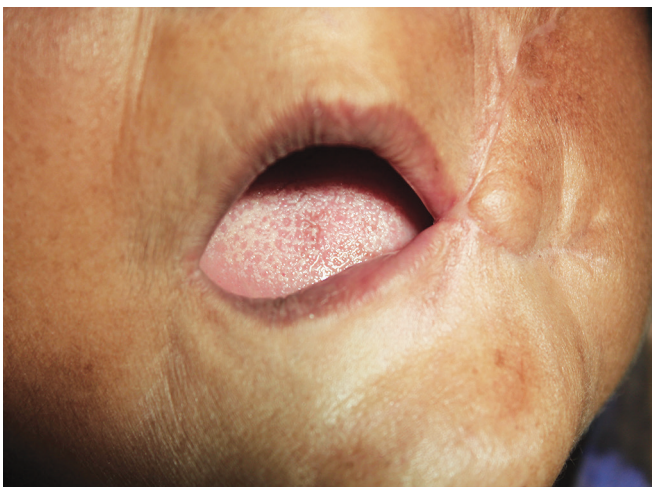

Fig. 4: Postoperative photograph

On palpation, the lesion was nontender and indurated. A provisional diagnosis of a cutaneous horn with underlying carcinoma of the left buccal mucosa was given.

An incisional biopsy was done and was reported as fibrocollagenous tissue lined by stratified squamous epithelium displaying hyperkeratosis, parakeratosis, acanthosis, and foci of full-thickness dysplasia. Focally, the subepithelial stroma showed a nest of squamous cells with moderately pleomorphic, vesicular nuclei exhibiting mitotic activity. There was stromal desmoplasia and moderate inflammation composed of lymphocytes, plasma cells, and neutrophils. Scanty skeletal muscle was also present, suggestive of carcinoma *in situ* with focus suspicious of early invasive squamous cell carcinoma of left lip commissure.

In the meanwhile, the cutaneous horn exfoliated on its own without provocation (Fig. 3). Wide local excision for carcinoma under general anesthesia was planned and done. Mucosal thickness incision was given intraorally over the left buccal mucosa and full thickness over the commissure of lip, and the lesion was excised in toto.

Z-plasty advancement was done for closure of the defect. The patient was placed on nasogastric feed post surgery and her recovery in the ward was uneventful and post-operative healing was satisfactory (Fig. 4).

The surgical specimen was sent for histopathological analysis and was reported as well-differentiated squamous cell carcinoma with TNM staging as pT NxMx (Fig. 5). Since the histopathological report of the surgical specimen revealed adequate margins that were free of tumor, it was planned to keep the patient on close follow-up.

DISCUSSION

A cutaneous horn (cornu cutaneum) is a protrusion arising from the skin consisting of cornified material prearranged in the shape of a horn. These horns may arise from underlying epidermal tumors, either benign or malignant.⁵ It is not a true pathological diagnosis.³ The histological appearance of the basal layer of the cutaneous horn is in the range of seborrheic keratosis to infiltrated squamous cell carcinoma.⁶ The angle of mouth is an uncommon site of occurrence for cutaneous horn. Giant cutaneous horns of lip are also uncommon and the malignancies associated with them even rarer. On review of the literature, 10 cases of cutaneous horn over the lip have been reported and three of these cases had an associated squamous cell carcinoma at their base.⁷⁻⁹

Bland-Sutton¹⁰ in 1911 classified cutaneous horns into four types according to the underlying lesion and the site:

1. Sebaceous horns arise from sebaceous cysts, which occur on the scalp
2. Warty horns occur on penis, morphologically resembling sebaceous horns
3. Cicatrix horns are rare, arise from burn scars
4. Nail horns arise from big toe nails in bedridden patients with poor personal hygiene

The matter of concern is not the horn itself which is dead keratin, but rather the underlying condition, which may be benign conditions (histiocytoma, seborrheic keratosis, viral warts, molluscum contagiosum, verrucous epidermal nevus, inverted follicular keratosis, etc), premalignant conditions (solar keratosis, arsenical keratosis), Bowen's disease, or malignant conditions (squamous cell carcinoma, rarely sebaceous carcinoma, basal cell carcinoma, metastatic renal carcinoma, Kaposi's sarcoma, or granular cell tumor). Most commonly, they are single and arise from a seborrheic keratosis lesion.¹¹ Largest studies of 643 cutaneous horns were reported by Yu et al.¹² According to them, 39% of cutaneous horns were associated with malignant or premalignant skin lesions, and 61% were derived from benign lesions. Two other studies on cutaneous horns, with larger sample sizes, also showed that 23 to 37% of these cases were associated with actinic keratosis or Bowen's disease and about 16 to 20% of the cases were associated with malignant lesions.¹² In the study of Bart et al,¹³ 44% patients had an associated malignancy. Factors associated with severity of the lesion at the base of a horn include increased age, male gender, exposure to sunlight, and geometry of the lesion.³

Exposure to sunlight is the most significant factor in our part of the country. Majority of the population is involved in farm activity without any sun protection. Like many other skin lesions, sun exposure is believed to be the most important etiological factor in the pathogenesis of cornu cutaneum. The habit of chewing pan and other tobacco products can be the major etiological factor for squamous cell carcinoma. Histopathological examination of the base of the lesion is necessary to rule out associated carcinoma, and is treated by full excision. The lesions are more common in older male patients, especially when the cutaneous horn is present on the face, pinna, dorsum of hands, forearms, or scalp or when it has a larger base or base/height ratio.¹²

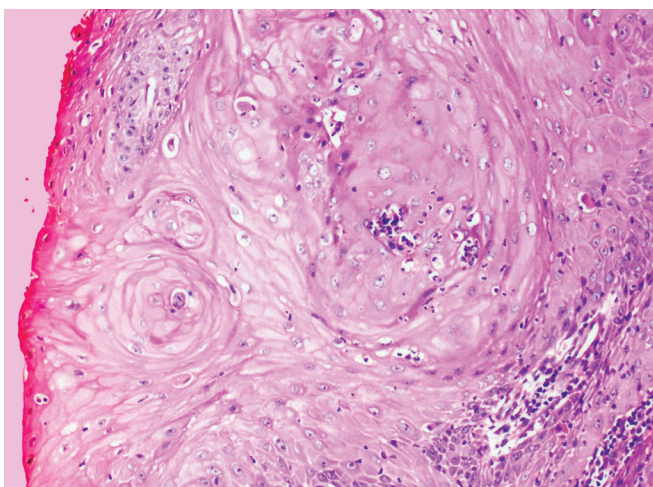


Fig. 5: Photomicrograph of well differentiated squamous cell carcinoma

Though cutaneous horns can be removed by simple detachment and cauterization of the base, due to their frequent association with premalignant or malignant lesions, it is advised to perform a full-thickness, wide local excision with an adequate margin for histopathological examination.³

CONCLUSION

Though cutaneous horns are predominantly benign lesions, the possibility of nearly one-third of them harboring malignant or premalignant lesions should always be kept in mind. In the above reported case, the cutaneous horns had an underlying malignant lesion which could have been hidden. A detailed history including habit history and thorough examination is required to arrive at the proper diagnosis, which serves as a guide for the complete treatment planning, such as wide local excision of the lesion in toto. Wide, full-thickness excision with adequate margin should be the treatment of choice to enable detailed pathological examination of the underlying tissue.

CONSENT

Written informed consent was obtained from the patient for publication of this case report and accompanying images.

AUTHORS' CONTRIBUTIONS

Dr. JS Jesija – Oral medicine specialist who contributed in diagnosis, writing, and researching of this article.

Dr. Saurabh Kumar – Oral surgeon who contributed in excision of the lesion, writing, and researching of this article.

Dr. Rebecca Paul – Fellowship trainee who worked up in this case study.

Dr. Rabin Chacko – Oral surgeon who contributed in supervising and guiding.

REFERENCES

1. Nthumba PM. Giant cutaneous horn in an African woman: a case report. *J Med Case Rep* 2007 Dec 5;1:170.
2. Ezerarslan H, Basaran MM, Akmansu SH. Diagnosis and management of cornu cutaneum of nasal vestibule: a rare case report. *Case Rep Med* 2015;2015:625832.
3. Kumar S, Bijalwan P, Saini SK. Carcinoma buccal mucosa underlying a giant cutaneous horn: a case report and review of the literature. *Case Rep Oncol Med* 2014;2014:518372.
4. Onak Kandemir N, Gun BD, Barut F, Solak Tekin N, Ozdamar SO. Cutaneous horn-related Kaposi's sarcoma: a case report. *Case Rep Med* 2010;2010:825-949.
5. Copcu E, Sivrioglu N, Culhaci N. Cutaneous horns: are these lesions as innocent as they seem to be? *World J Surg Oncol* 2004 Jun 3;2:18.
6. Bondeson J. Everard Home, John Hunter, and cutaneous horns: a historical review. *Am J Dermatopathol* 2001 Aug;23(4):362-369.

7. Pinto-Almeida T, Oliveira A, Velho GD, Alves R, Caetano M, Selores M. Giant cutaneous horn on the lower lip. *Dermatol Online J* 2011 Dec 15;17(12):10.
8. Skoulakis C, Theos E, Chlopsidis P, Manios AG, Feritsean A, Papadakis CE. Giant cutaneous horn on squamous cell carcinoma of the lower lip. *Eur J Plast Surg* 2009;32(5):257-259.
9. Popadić M. Squamous cell carcinoma presenting as a giant cutaneous horn of the lower lip. *Indian J Dermatol Venereol Leprol* 2014;80(1):74-76.
10. Bland-Sutton J. Tumours: innocent and malignant: their clinical features and appropriate treatment. 5th ed. London: Cassell; 1917.
11. Thappa DM, Laxmisha C. Cutaneous horn of eyelid. *Indian Pediatr* 2004 Feb;41(2):195.
12. Yu RCH, Pryce DW, Macfarlane AW, Stewart TW. A histopathological study of 643 cutaneous horns. *Br J Dermatol* 1991 May;124(5):449-452.
13. Bart RS, Andrade R, Kopf AW. Cutaneous horns. A clinical and histopathologic study. *Acta Derm Venereol* 1968;48(5):507-515.