

Necrotizing Sialometaplasia of Parotid

¹Vivek Sasindran, ²Nidhi Mathew

ABSTRACT

Introduction: Necrotizing sialometaplasia (NS) is a benign inflammatory disease often found in minor salivary glands. It may mimic salivary gland malignancy on fine-needle aspiration cytology (FNAC), which may result in more aggressive treatment than required, compromising the postoperative quality of life of the patient. Here, we report a case of a salivary gland swelling which suggested malignant changes in an FNAC, but later diagnosed as NS after the excision.

Case report: A 52-year-old male presented to surgery outpatient department (OPD) with complaints of nontender, firm swelling of size 3 × 2 cm present below and behind the (L) angle of mandible in the parotid region. There was no fistula or cervical lymphadenopathy. Parotid duct opening was normal. On FNAC, findings suggested metastasis from well-differentiated squamous cell carcinoma or secondary changes in a dermoid cyst. Contrast-enhanced computed tomography (CT) neck revealed a well-defined lesion involving superficial lobe of (L) parotid gland with possibility of benign neoplastic etiology. Biopsy report showed the possibility of NS that occurred in preexisting benign salivary gland lesion.

Management: The lesion was surgically excised under general anesthesia and the postoperative period was uneventful.

Conclusion: Necrotizing sialometaplasia is an inflammatory reaction of salivary tissues with a self-limiting disease course, which has been often misdiagnosed as mucoepidermoid carcinoma, squamous cell carcinoma, acinic cell carcinoma, verrucous carcinoma, and ductal carcinoma. Therefore, familiarity with NS and correct diagnosis are paramount in avoiding misdiagnosis and inappropriate treatment.

Keywords: Inflammatory disease, Necrotizing sialometaplasia, Parotid gland swelling.

How to cite this article: Sasindran V, Mathew N. Necrotizing Sialometaplasia of Parotid. *Oral Maxillofac Pathol J* 2018;9(1):36-38.

Source of support: Nil

Conflict of interest: None

INTRODUCTION

Necrotizing sialometaplasia is an uncommon, benign, locally aggressive but self-limiting condition. This was

first recognized by Dr John Cornyn and was described in detail by Albert Adams and Raymond Melrose in 1973. The age of presentation ranges from 1.5 to 83 years and most commonly presents in the fourth decade. Males are affected more commonly than females.

Although the pathogenesis of lesions is thought to be owing to ischemic changes in the salivary glands arising from causes, such as traumatic injury and medical procedures, the precise etiology has not been fully elucidated.^{1,2} Heavy smoking, alcohol abuse, upper respiratory tract infections and associated lesions, local neurological deficit, and allergies have also been said to be contributory to this condition.

The most common site is the posterior part of hard palate followed by junction of the hard palate and the soft palate, with two-thirds lesions being unilateral. Other locations are soft palate, lip, retromolar trigone, tongue, mucobuccal fold, tonsillar fossa, parotid, sublingual, submandibular glands, nasal cavity, incisive canal, maxillary sinus, and larynx.

CASE REPORT

A 52-year-old male presented to surgery OPD with complaints of swelling behind angle of mandible on the left side, since 22 years. The swelling was initially nontender and small in size but gradually increased in size and pain since last 2 weeks. On examination, the swelling was firm and nontender. It was of size 3 × 2 cm located below and behind the angle of mandible in the parotid region. The skin over the swelling was not ulcerated (Fig. 1). There was

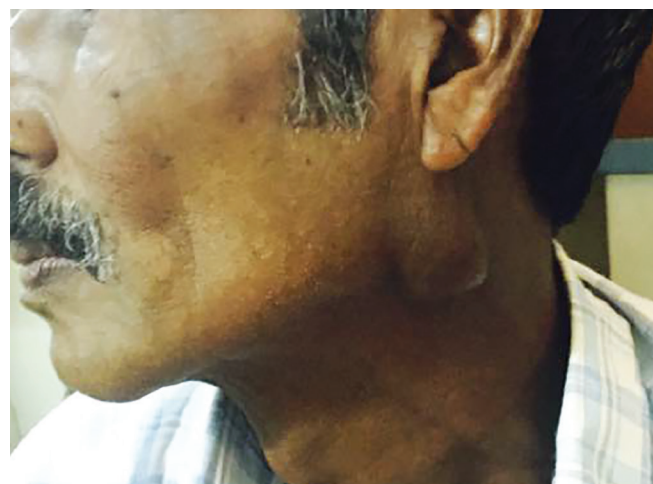

Fig. 1: Swelling in left parotid region

¹Associate Professor, ²Senior Resident

^{1,2}Department of ENT, Pushpagiri Medical College, Thiruvalla Kerala, India

Corresponding Author: Vivek Sasindran, Associate Professor Department of ENT, Pushpagiri Medical College, Thiruvalla Kerala, India, Phone: +919947132343, e-mail: viveksasindran@hotmail.com

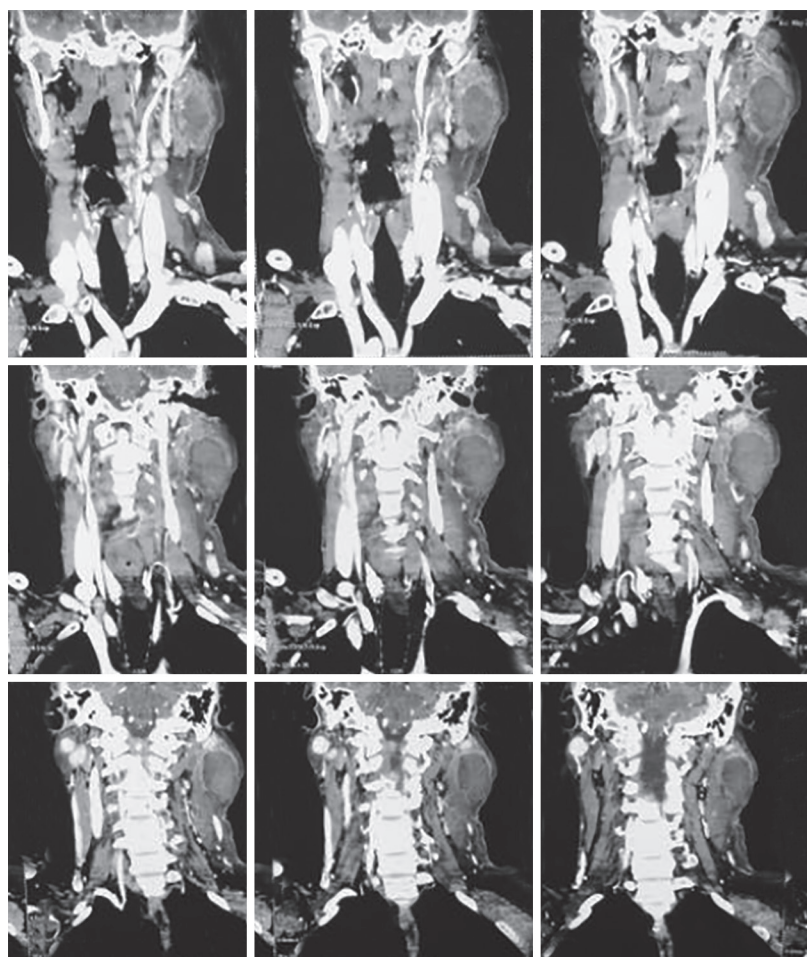


Fig. 2: Computed tomography scan showing a well defined lesion involving superficial lobe of left parotid gland with evidence of surrounding hyperaemia

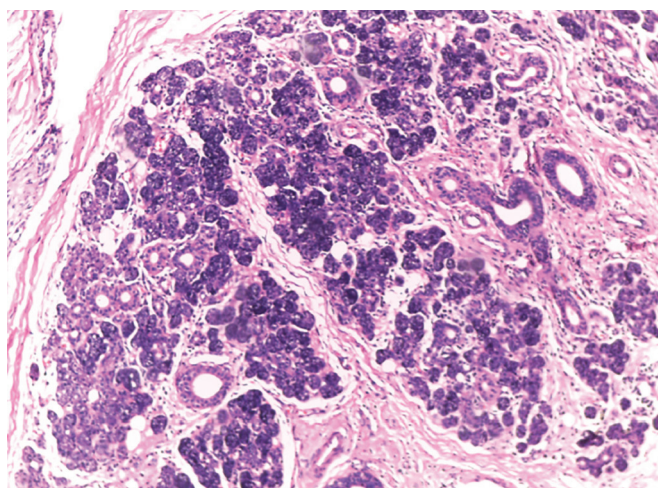


Fig. 3: Histopathological picture

no cervical lymphadenopathy and parotid duct opening appeared normal. The FNAC findings suggested metastasis from well-differentiated squamous cell carcinoma or secondary changes in a dermoid cyst. The CT neck revealed a well-defined lesion involving superficial lobe of (L) parotid gland with evidence of surrounding hyperemia, possibility of benign neoplastic etiology (Fig. 2).

Biopsy after the excision showed salivary gland tissue with fibrocollagenous and muscular tissue showing a lesion composed of squamous cells forming nests, cords, and multiple cystic spaces. Some cystic spaces were lined by benign squamous cells partly and ciliated columnar cells in the rest of the areas. Lumen of some cysts was filled with foamy macrophages and necrotic material. Intervening stroma showed dense lymphoplasmacytic infiltrate along with foamy macrophages. Areas of ischemic necrosis were noted. The possibility of NS that occurred in preexisting benign salivary gland lesion was considered (Fig. 3).

DISCUSSION

The incidence of this lesion in parotid gland is rare and has been estimated to be at most approximately 10%.³ The etiology of NS remains unknown, but it may be associated with salivary gland ischemia, leading to infarction and subsequent necrosis of tissue followed by repair and metaplasia.^{3,4} Batsakis and Manning⁵ reported that seven of eight cases had followed an operative procedure for another primary tumor of the parotid gland. Di Palma et al⁶ reported that trauma, such as FNAC caused

infarction and squamous metaplasia in a case of Warthin's tumor following which a lesion analogous to NS was observed in non-neoplastic salivary gland. The NS was first reported to involve the minor salivary glands of the oral cavity, particularly those of the palate. Seventy-five percent of all cases occur on the posterior palate. Most are unilateral, with one-third occurring in a bilateral or midpalatal location.

Anneroth and Hansen⁴ proposed five histological stages of pathogenesis of NS: Infarction, sequestration, ulceration, repair, and healing. Carlson gave five characteristic histological features of NS. They are

1. Pseudoepitheliomatous hyperplasia
2. Squamous metaplasia of ducts and acini
3. Preservation of lobular architecture
4. Lobular infarction with or without mucin spillage
5. Inflammation secondary to extravasation of mucin⁷

Necrotizing sialometaplasia has been misdiagnosed as mucoepidermoid carcinoma, squamous cell carcinoma, acinic cell carcinoma, verrucous carcinoma, and ductal carcinoma. The prognosis for NS is excellent.

CONCLUSION

Necrotizing sialometaplasia is a spontaneously resolving inflammatory process of the salivary gland that can mimic a malignant tumor. It is critically important to

closely examine whether there are aspects of NS in the preoperative findings to avoid overzealous treatment. If the lesion in the parotid gland is not suspected of being a malignant tumor but rather an NS it might be preferable to adopt a "wait and watch" approach owing to possibility of spontaneous healing within 3 to 12 weeks that may occur in cases of NS.

REFERENCES

1. Abrams AM, Melrose RJ, Howell FV. Necrotising sialometaplasia. A disease simulating malignancy. *Cancer* 1973 Jul;32(1):130-135.
2. Adyin O, Yilmaz T, Ozer F, Saraç S, Sökmensüer C. Necrotizing sialometaplasia of parotid gland: a possible vasculitic cause. *Int J Pediatr Otorhinolaryngol* 2002 Jun;64(2):171-174.
3. Brannon RB, Fowler CB, Hartman KS. Necrotizing sialometaplasia. A clinicopathologic study of 69 cases and review of literature. *Oral Surg Oral Med Oral Pathol* 1991 Sep;72(3):317-325.
4. Anneroth G, Hansen LS. Necrotizing sialometaplasia. The relationship of its pathogenesis to its clinical characteristics. *Int J Oral Surg* 1982 Oct;11(5):283-291.
5. Batsakis JG, Manning JT. Necrotizing sialometaplasia of major salivary glands. *J Laryngol Otol* 1987 Sep;101(9):962-966.
6. Di Palma S, Simpson RH, Skalova A, Michal M. Metaplastic (infarcted) Warthins tumour of the parotid gland: a possible consequence of FNAC. *Histopathology* 1999 Nov;35(5):432-438.
7. Bihani A, Lodha J, Sharma A, Virmani N, Dabholkar JP. Necrotizing Sialometaplasia—a diagnostic dilemma. *Int J Sci Res (IJSR)* 2014 Jul;3(7):1089-1090.