

# Lateral Odontogenic Keratocyst mimicking Periodontal Cyst: A Case Report and Review

<sup>1</sup>Kalyan Kanth, <sup>2</sup>Divya Uppala, <sup>3</sup>Sumit Majumdar

## ABSTRACT

**Context:** As lateral variants of odontogenic keratocysts (OKCs) are relatively rare when compared to the conventional variants, this report is presented to provide an insight into the clinical features and radiographic features of the cyst.

**Aims:** This report aims to assist the clinician to form an appropriate differential diagnosis for a cyst placed laterally toward a tooth.

**Settings and designs:** The tissue was received from a private dental clinic after being fixed in 10% formalin, which measured around 1 × 1 cm in diameter.

**Materials and methods:** About 5 µm thick sections were obtained from paraffin-embedded tissues that had been processed and stained with routine hematoxylin and eosin. The stained sections were then reviewed.

**Conclusion:** Examination of paraffin-embedded sections showed microscopically a cystic parakeratinized stratified squamous lining epithelium with corrugated surface, and a picket fence arrangement of basal cell layer, thus giving a final diagnosis of a lateral OKC.

**Keywords:** Keratocyst, Lateral, Odontogenic, Periodontal.

**How to cite this article:** Kanth K, Uppala D, Majumdar S. Lateral Odontogenic Keratocyst mimicking Periodontal Cyst: A Case Report and Review. *Oral Maxillofac Pathol J* 2016;7(2):758-760.

**Source of support:** Nil

**Conflict of interest:** None

## INTRODUCTION

Odontogenic keratocyst (OKC) is a developmental odontogenic cyst and can occur anywhere in the jaws. The most common areas of occurrence are the posterior mandible followed by maxillary third molar region. Odontogenic keratocyst is locally aggressive, often causing undue

bone expansion and also invasion into the soft tissues. Odontogenic keratocyst was first described by Philipsen in 1956. The dental lamina (DL) which has been postulated in the pathogenesis of OKC was considered as primordial epithelium, hence the name primordial cyst.<sup>1</sup> Odontogenic keratocyst also occurs in between the roots of the premolars and is known as lateral OKC, which may resemble lateral periodontal cyst (LPC) or lateral radicular cyst.<sup>2</sup>

The aim of this paper is to report a case of OKC situated between the roots of mandibular canine and premolar resembling LPC.

## CASE REPORT

A 28-year-old female patient reported to the dental clinic with a chief complaint of swelling in the left lower back tooth region for the past 4 months. Clinically, there was a diffuse swelling approximately 1.5 cm in diameter on the attached gingiva (Fig. 1). An orthopantomogram was taken, which revealed a pear-shaped radiolucency between the roots (Fig. 2). Aspiration produced a clear-colored fluid. Based on the clinical and radiographic findings, a provisional diagnosis of LPC was given. Enucleation of the lesion was done under local anesthesia and the specimen was sent for histopathological examination (Fig. 3).

The histopathology revealed a cystic parakeratinized stratified squamous lining epithelium with corrugated surface. The basal cells exhibited nuclear hyperchromatism and were arranged in palisaded pattern. Thus, a final diagnosis of OKC was given (Figs 4 and 5).

## DISCUSSION

Histopathologically, the OKC has a thin epithelial lining around four to eight cells thick and devoid of rete ridges. Wysocki et al, in 1980, described a special type of cyst called "lateral periodontal cyst" which was also characterized by thin uniform nonkeratinizing epithelial lining.<sup>3</sup>

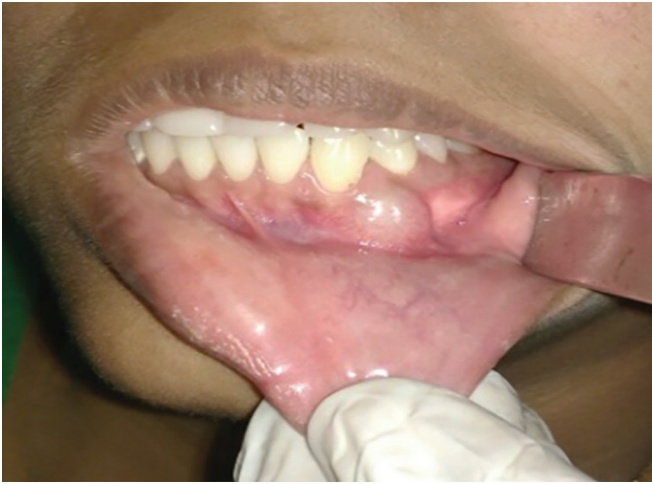He further stated that such cysts should have a multi-locular appearance and the term "lateral periodontal cyst" should not be confused with odontogenic keratocyst. Odontogenic keratocyst has a higher recurrence rate and Gold and Sliwksoski stated that LPC also has a high recurrence rate.<sup>6</sup>

<sup>1,2</sup>Reader, <sup>3</sup>Professor

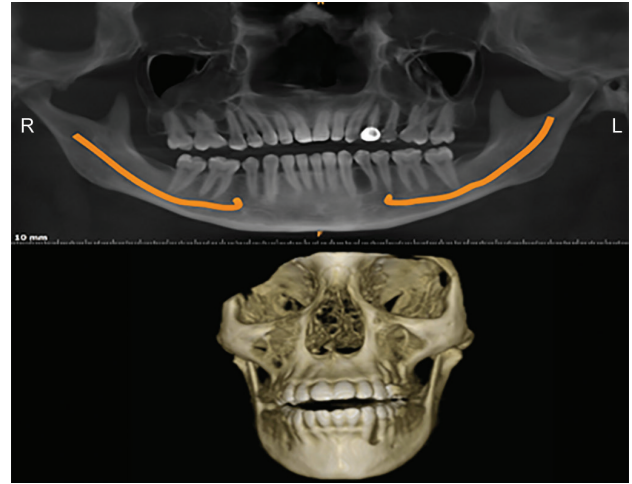
<sup>1</sup>Department of Oral and Maxillofacial Surgery, Anil Neerukonda Institute of Dental Sciences, Visakhapatnam, Andhra Pradesh India

<sup>2,3</sup>Department of Oral Pathology and Dental Anatomy, GITAM Dental College & Hospital, Visakhapatnam, Andhra Pradesh India

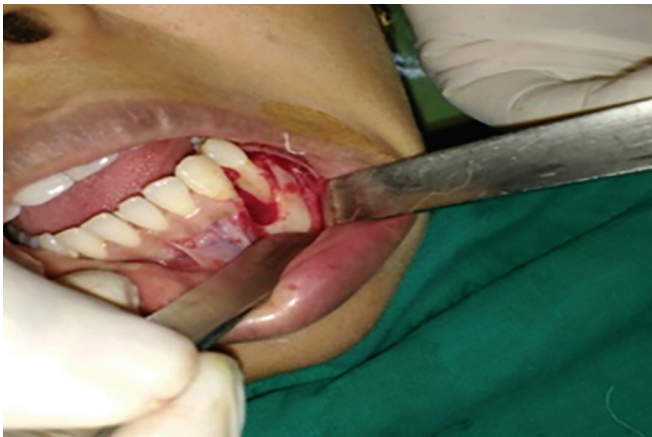**Corresponding Author:** Kalyan Kanth, Reader, Department of Oral and Maxillofacial Surgery, Anil Neerukonda Institute of Dental Sciences, Visakhapatnam, Andhra Pradesh, India, e-mail: denticool@gmail.com



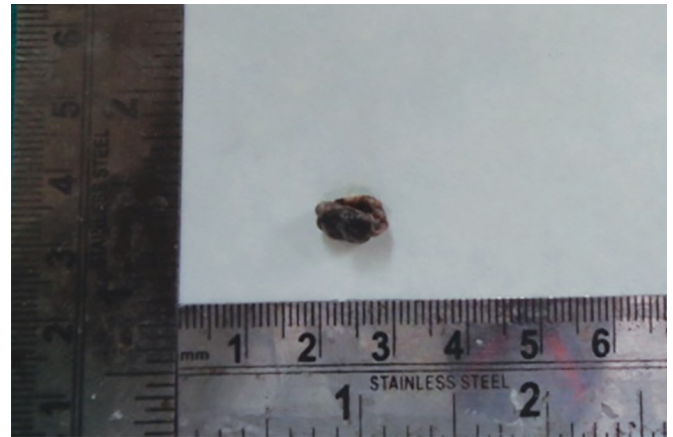
**Fig. 1:** Diffuse swelling in attached gingiva



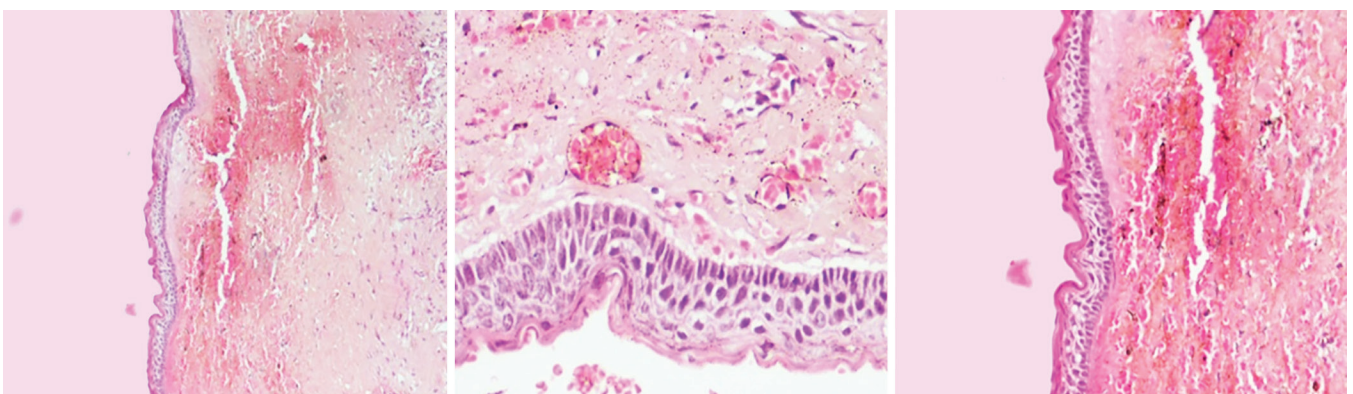
**Fig. 2:** Pear shaped radiolucency between teeth



**Fig. 3:** Enucleation of lesion was done under local anesthesia



**Fig. 4:** Gross specimen



**Fig. 5:** Cystic parakeratinized stratified squamous lining epithelium with corrugated surface. The basal cells exhibited nuclear hyperchromatism and basal cells were arranged in a palisaded pattern

Wysocki et al also postulated the limited growth potential of LPC when compared with OKC (both being of DL origin). The LPC arises from postfunctional cells of DL whereas the latter (OKC) arises from part of DL, still having growth potential.<sup>4-6</sup>

## CONCLUSION

Lateral OKC can present as diagnostic challenge as it is often misinterpreted as lateral periodontal cyst. Hence, a good differential diagnosis should include occult OKCs.

## REFERENCES

1. Shear M, Speight P. Cysts of oral and maxillofacial regions. 4th ed. Blackwell Munksgaard Publishers, USA 2007.
2. Neville BW, Mishkin DJ, Traynham RT. The laterally positioned OKC: a case report. *J Periodontol* 1984 Feb;55(2): 98-102.
3. Wysocki GP, Brannon RB, Gardner DG, Sapp P. Histogenesis of the lateral periodontal cyst and the gingival cyst of the adult. *Oral Surg Oral Med Oral Pathol* 1980 Oct;50(4): 327-334.
4. Pindborg JJ, Hansen J. Studies on odontogenic cyst epithelium. 2. Clinical and roentgenologic aspects of odontogenic keratocysts. *Acta Pathol Microbiol Scand* 1963;58:283-294.
5. Philipsen HP. Om keratocyster (kolesteatomer) i kaebene. *Tandlaege Bladet* 1956;60:963-981.
6. Gold L, Silwkowski AS. Lateral periodontal cyst: a clinical and histological study. *Trans Int Conf Oral Surg.* 1973;4:85-89.