

Ameloblastic Fibro-odontoma

¹Valappil T Beena, ²Jasmin Jose, ³Sabu Paul, ⁴Manju S Mathunny, ⁵Sreela K Kottarathil, ⁶Shalu

ABSTRACT

Introduction: Ameloblastic fibro-odontoma (AFO) is a rare benign, slow-growing, expansile epithelial odontogenic tumor with odontogenic ectomesenchyme. It constitutes about 1 to 3% of all odontogenic tumors. This lesion usually occurs in people less than 20 years old, and thus age is an important characteristic in the differential diagnosis.

Case report: An 8-year-old boy reported with a swelling in the right mandibular region. Panoramic radiograph showed a well-demarcated radiolucency containing radiopaque areas of irregular shape extending from the right deciduous second molar to the permanent third molar region. A provisional clinical diagnosis of complex odontome was made. Ameloblastic fibro-odontoma, odontoameloblastoma, calcifying epithelial odontogenic tumor, and calcifying odontogenic cyst were also included in the differential diagnoses.

Management and prognosis: Patient underwent tumor excision, and histopathological examination confirmed as AFO. The patient was followed postoperatively for 12 months and no sign of recurrence was noted.

Conclusion: Long-term follow-up at regular short intervals should be maintained in the management of AFO. Here we add one more case to the sparsely reported AFO with a brief review of literature.

Keywords: Ameloblastic fibro-odontoma, Odontogenic tumors, Odontoma.

How to cite this article: Beena VT, Jose J, Paul S, Mathunny MS, Kottarathil SK, Shalu. Ameloblastic Fibro-odontoma. *Oral Maxillofac Pathol J* 2017;8(2):94-97.

Source of support: Nil

Conflict of interest: None

INTRODUCTION

Ameloblastic fibro-odontoma (AFO) is a rare benign, slow-growing, expansile epithelial odontogenic tumor with odontogenic ectomesenchyme. According to the World Health Organization classification of odontogenic tumors published in 2005, AFO belongs to the group of

lesions with odontogenic epithelium with odontogenic ectomesenchyme, with or without hard tissue formation.¹ AFO is a tumor with histological features similar to those of ameloblastic fibroma (AF), but it shows inductive changes that lead to the formation of dentin or enamel. It may inhibit tooth eruption or displace involved teeth, although teeth in the affected area are vital.²⁻⁴ The lesions are usually diagnosed during the first and second decades of life. Radiographically, the lesion presents with a well-circumscribed, unilocular or multilocular radiolucent area containing various amounts of radiopaque material of irregular size and form. The large areas of calcification make it impossible to radiographically differentiate it from complex odontoma.^{4,5,6} This article reports a case of AFO in an 8-year-old male with significant clinicoradiographic features, histopathology, differential diagnoses, and treatment.

CASE REPORT

An 8-year-old boy was referred to the outpatient department at the Government Dental College, Kottayam, Kerala, India, with a swelling in the right mandibular region.

There was no significant medical, social, or family history or history of local trauma or infection. Extraoral examination showed mild facial asymmetry on the right side. On palpation, a hard painless swelling was observed in the right mandibular body. Intraoral examination revealed a well-circumscribed swelling of the alveolar ridge, extending from the deciduous second molar to the anterior border of the ascending ramus, covered with normal mucosa which was hard on palpation. The mandibular right permanent first molar was absent.

Panoramic radiograph showed a large, well-demarcated radiolucency containing tooth-like radiopaque areas of irregular shape extending from the right deciduous second molar to the permanent third molar region. The tooth germ of the right lower permanent first molar was displaced to the base of the mandible by the lesion. The right lower permanent second and third molar tooth germs were involved by the mineralized mass (Fig. 1). Going by the clinical and radiographic findings, a provisional clinical diagnosis of complex odontome was made. Ameloblastic fibro-odontoma, odontoameloblastoma, calcifying epithelial odontogenic tumor, and calcifying odontogenic cyst were also included in the differential

¹Professor and Head, ^{2,5,6}Postgraduate Student, ³Assistant Professor, ⁴Senior Lecturer

¹⁻⁶Department of Oral Pathology and Microbiology, Government Dental College, Kottayam, Kerala, India

Corresponding Author: Valappil T Beena, Professor and Head, Department of Oral Pathology and Microbiology Government Dental College, Kottayam, Kerala, India, Phone: +919847150407, e-mail: drvtbeena@gmail.com

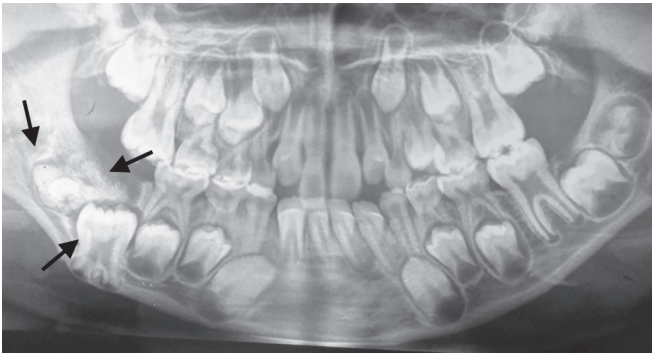


Fig. 1: Panoramic radiograph showing well-demarcated radiolucent lesion affecting the right lower permanent molar region, containing radiopaque areas of varying size, causing the displacement of the tooth germ of the lower first molar

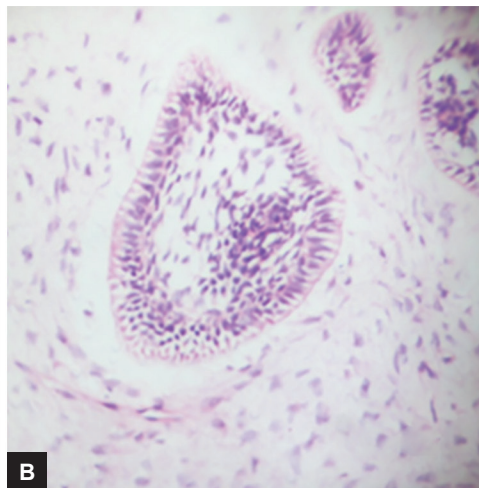
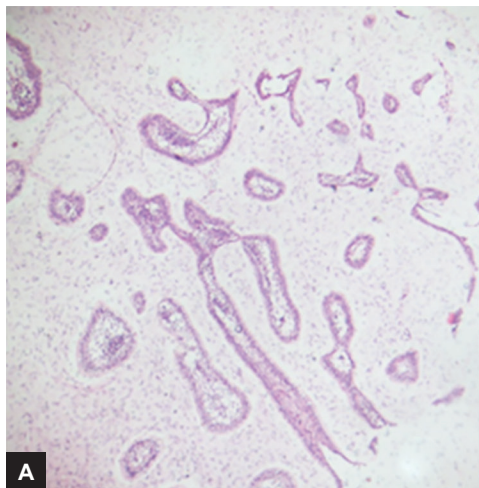
diagnoses. Under general anesthesia, by intraoral approach, the tumor was excised.

Light microscopic examination of sections revealed strands and islands of odontogenic epithelium showing peripheral palisading columnar cells resembling enamel

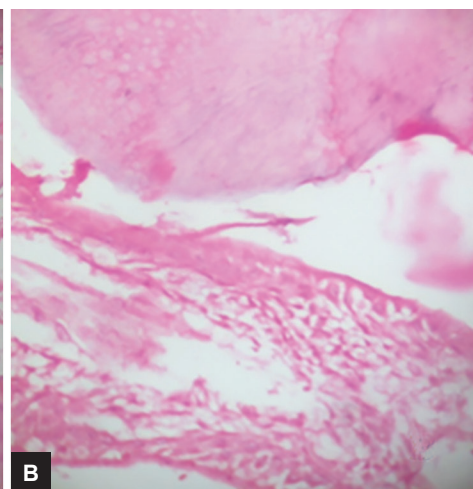
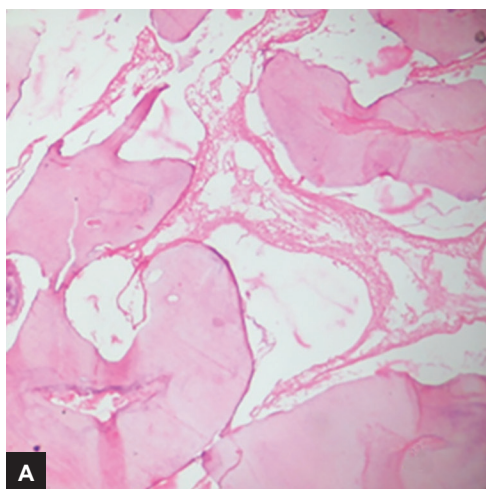
epithelium and loosely arranged spindle-shaped cells identical to stellate reticulum in the central area (Fig. 2). The ectomesenchymal component comprised loose connective tissue, with abundant extracellular matrix containing young, plump fibroblasts, sometimes with a stellate appearance, resembling the dental papilla. The decalcified sections showed enamel matrix and dentin-like substance (Fig. 3). In few areas, reduced enamel epithelium was observed around the matrix. The dental tissues were disorganized in some regions forming a large mass of dentin around reduced enamel epithelium and enamel matrix. No malignant changes were evident. Based on clinical and histopathological features, the tumor was diagnosed as AFO. No sign of recurrence was observed during a postoperative period of 12 months.

DISCUSSION

The present case meets the clinicopathological criteria for the diagnosis of AFO, which is a rare mixed odontogenic



Figs 2A and B: Strands and islands of odontogenic epithelium showing peripheral palisading and loosely arranged central stellate reticulum-like cells embedded in myxoid cell-rich stroma resembling the dental papilla: (A) (hematoxylin and eosin [H&E] 100×); and (B) (H&E 400×)



Figs 3A and B: Photomicrograph of the decalcified sections showing dentin-like material and enamel matrix around reduced enamel epithelium (A) (hematoxylin and eosin [H&E] 100×); (B) (H&E 400×)

tumor. The AFO accounts for 1 to 3% of all odontogenic tumors.⁵ The tumor has equal distribution in the maxilla and mandible and shows predilection to the molar region. There is no gender variance and mean age of subjects is 11.5 years. Slootweg⁷ reviewed 50 patients with this lesion, for whom the mean age was 8.1 years. This lesion usually occurs in people less than 20 years old, and thus age is an important characteristic in the differential diagnosis.

The two frequent patient complaints are failure of tooth eruption and swelling. Asymptomatic cases are incidentally detected on radiography. This lesion is generally considered a slow-growing central jaw tumor; however, several exceptions to this pattern have been reported.⁵

Radiographs reveal a well-defined radiolucent area enclosing varying amount of radiopaque material of irregular size and shape.⁸ The ratio of radiolucent to radiopaque areas ranges from one lesion to another. Some of the lesions are relatively small when first detected, measuring 1 to 2 cm in diameter, whereas others may be exceedingly large, involving a considerable portion of the body of the mandible or maxilla.⁷

Histologically, AFO is composed of cords, strands, and islands of odontogenic epithelium within a cellular primitive ectomesenchyme that simulates dental papilla. Dentin and enamel matrix are also seen.⁹ Conversely, the elite presence of dentin depicts another entity, ameloblastic fibrodentinoma. The histogenesis of this tumor is debatable. Ameloblastic fibro-odontoma is a benign tumor that exhibits the same benign biologic behavior as that of AF, showing inductive changes that lead to the formation of both dentin and enamel. The presence of both dentin and enamel is imperative to differentiate AFO from AF, which is devoid of tooth differentiation.¹⁰ It has been a matter of dispute whether the mixed odontogenic tumors (AFO, AF, and odontomas) should be classified as separate entities or if they represent different stages of development of a single entity. Ameloblastic fibroma, the tumor with least differentiation, was considered to have progressed into a moderately differentiated form, AFO, and finally into complex odontoma. But, this concept of "continuum of differentiation" is not widely accepted, and many authors consider these lesions as separate pathologic entities.^{7,11} Many of the patients who are affected by AF are generally older than those affected by AFO, although various studies suggest that AFOs are hamartomatous in nature, representing a stage that precedes the complex odontoma.¹² It seems that not all cases of AFO should be considered as hamartomatous, since there are cases that show true neoplastic behavior and because there is evident existence of a malignant variant of the disease.^{4,13} Furthermore, the recurrences in AFO denote its neoplastic nature.⁷ Thus, it is possible

that different lesions are being described under the same term of AFO, where some are hamartomatous in nature and others a true *de novo* neoplasm. Currently, it is not possible to distinguish a hamartoma from a neoplasm only based on histological features. A small lesion on the occlusal surface of an unerupted molar may be the immature stage of an odontoma, whereas a lesion that causes swelling and cortical expansion is likely to be a true AFO.¹⁴

Immunohistochemistry reveals that all epithelial components in the AF-like area showed expression of CK8, CK13, CK16, CK14, CK18, and CK19, and coexpression of these cytokeratins and vimentin. Miyauchi et al¹⁴ suggest that the epithelial component showed cell differentiation of the enamel organ with the potential for epithelial-mesenchymal induction. The cell kinetics in mandibular AFO was studied by bromo-deoxyuridine and proliferating cell nuclear antigen. The result of immunohistochemical investigations suggested that the mesenchymal component was more proliferative than the epithelial component.¹⁵ Such an immunohistochemical investigation may be useful in evaluating the proliferative potential of odontogenic tumors.

Slootweg¹⁶ compared ultrastructure of the epithelial-mesenchymal interface of AFOs with that of the normally developing tooth germ and it was noted that the ultrastructure of the tumors was identical with the normally developing odontogenic tissues up to but not including the differentiation of mesenchymal cells into tall columnar odontoblasts. The absence of odontoblasts in the AFOs resulted in an absence of tubular dentin in place of which a homogeneous collagen-containing material was synthesized. Failure of the mesenchymal cells to transform into tall columnar odontoblasts could be due to the lack of the normally occurring induction of the ectomesenchyme by the odontogenic epithelium according to Slootweg.

When AFO presents with the typical age, location, and radiographic pattern, the diagnosis is usually obvious. The differential diagnosis should include lesions with mixed radiographic patterns, such as calcifying epithelial odontogenic cyst, calcifying odontogenic tumor, immature complex odontoma, ontoameloblastoma, and adenomatoid odontogenic tumor. Ameloblastic fibro-odontoma can be differentiated from calcifying odontogenic cyst on the basis that it is a well-circumscribed, solid or cystic lesion derived from odontogenic epithelium that microscopically resembles ameloblastoma but differs by containing ghost cells and spherical calcifications. Calcifying epithelial odontogenic tumor comprises sheets of polyhedral tumor cells along with homogeneous eosinophilic deposits that stain positive for amyloid, and spherical calcifications

which discriminate it from AFO. The term odontoameloblastoma refers to tumors representing a histological combination of ameloblastoma and complex odontoma, which will behave in the invasive manner of classic ameloblastoma. It is usually an unencapsulated lesion and shows ameloblastic areas and ghost cells which help in the differential diagnosis. Ameloblastic fibro-odontoma may not be histologically differentiated from an immature complex odontoma. Ameloblastic fibro-odontoma is well encapsulated and there is little propensity for local invasion, so the treatment approach is primarily conservative surgery. In the present case, no recurrence was observed after excision of the lesion and preservation of the first molar. Tissue healing was adequate, even without placement of bone graft or replacement material.

CONCLUSION

As discussed earlier, AFO with a neoplastic nature has a potential for recurrence.

REFERENCES

1. Barnes, L.; Eveson, JW.; Reichart, P.; Sidransky, D. Pathology and genetics. Head and neck tumors. In: Kleihues P, Sobin LH, editors. World Health Organization Classification of Tumours. Lyon: IARC Press; 2005.
2. Hutt PH. Ameloblastic fibro-odontoma: report of a case with documented four-year follow-up. *J Oral Maxillofac Surg* 1982 Jan;40(1):45-48.
3. Philipsen HP, Thosaporn W, Reichart PA, Grundt G. Odontogenic lesions in opercular of permanent molars delayed in eruption. *J Oral Pathol Med* 1992 Jan;21(1):38-41.
4. Miller AS, López CF, Pullon PA, Elzay RP. Ameloblastic fibroodontoma: report of seven cases. *Oral Surg Oral Med Oral Pathol* 1976 Mar;41(3):354-365.

5. Chang H, Shimizu MS, Precious DS. Ameloblastic fibro-odontoma: a case report. *J Can Dent Assoc* 2002 Apr;68(4):243-246.
6. Bernhoft CH, Bang G, Gilhuss-Moe O. Ameloblastic fibroodontoma. *Int J Oral Surg* 1979 Jun;8(3):241-244.
7. Slootweg PJ. An analysis of the interrelationship of the mixed odontogenic tumors – ameloblastic fibroma, ameloblastic fibro-odontoma, and the odontoma. *Oral Surg Oral Med Oral Pathol* 1981 Mar;51(3):266-276.
8. Daley DT, Wysocki GP, Pringle GA. Relative incidence of odontogenic tumors and oral and jaw cysts in a Canadian population. *Oral Surg Oral Med Oral Pathol* 1994 Mar;77(3):276-280.
9. Furst I, Pharoah M, Phillips J. Recurrence of an ameloblastic fibro-odontoma in a 9-year-old boy. *J Oral Maxillofac Surg* 1999 May;57(5):620-623.
10. Friedrich RE, Siegert J, Donath K, Jäkel KT. Recurrent ameloblastic fibro-odontoma in a 10-year-old boy. *J Oral Maxillofac Surg* 2001 Nov;59(11):1362-1366.
11. Eversole RE, Tomich CE, Cherrick HM. Histogenesis of odontogenic tumor. *Oral Surg Oral Med Oral Pathol* 1971 Oct;32(4):569-581.
12. Chen Y, Li TJ, Gao Y, Yu SF. Ameloblastic fibroma and related lesions: a clinicopathologic study with reference to their nature and interrelationship. *J Oral Pathol Med* 2005 Nov;34(10):588-595.
13. Howell RM, Burkes EJ Jr. Malignant transformation of ameloblastic fibro-odontoma to ameloblastic fibrosarcoma. *Oral Surg Oral Med Oral Pathol* 1977 Mar;43(3):391-401.
14. Miyauchi M, Takata T, Ogawa I, Ito H, Nikai H, Ijuhin N, Tanimoto K, Miyauchi S. Immunohistochemical observations on a possible ameloblastic fibroodontoma. *J Oral Pathol Med* 1996 Feb;25(2):93-96.
15. Sekine J, Kitamura A, Ueno K, Sano K, Inokuchi T, Takahashi H, Okabe H. Cell kinetics in mandibular ameloblastic fibroodontoma evaluated by bromodeoxyuridine and proliferating cell nuclear antigen immune histochemistry: case report. *Br J Oral Maxillofac Surg* 1996 Oct;34(5):450-453.
16. Slootweg PJ. Epithelio-mesenchymal morphology in ameloblastic fibroodontoma: a light and electron microscopic study. *J Oral Pathol* 1980 Jan;9(1):29-40.