

# Osteoid Osteoma of Mandibular Condyle

<sup>1</sup>Geeta Singh, <sup>2</sup>Shadab Mohammad, <sup>3</sup>Dichen P Bhutiya, <sup>4</sup>Debraj Howlader

## ABSTRACT

**Introduction:** Osteoid osteoma is a benign skeletal neoplasm that occurs most commonly in young individuals. The tumor occurs mostly in long bones like femur and tibia. However, the jaw bones can be involved though rarely.

**Aim:** Objective of this study is to present the features of osteoid osteoma of mandibular condyle in a 33-year-old male patient.

**Materials and methods:** 0.3  $\mu$  thick sections were obtained from paraffin-embedded tissues of the representative tissue that had been processed and stained with routine hematoxylin and eosin stains, and these stained sections were assessed histopathologically.

**Management:** Amputation of the condyle was performed under general anesthesia.

**Conclusion:** Osteoid osteoma represents the third most common benign neoplasm of bone and its diagnosis remains difficult, as generally the clinical and radiographic findings are not characteristic. Computed tomography (CT) imaging along with classic histopathologic findings helps in the early diagnosis of this lesion.

**Keywords:** Bone tumor, Condylectomy, Mandibular condyle, Osteoid osteoma.

**How to cite this article:** Singh G, Mohammad S, Bhutiya DP, Howlader D. Osteoid Osteoma of Mandibular Condyle. *Oral Maxillofac Pathol J* 2017;8(1):35-38.

**Source of support:** Nil

**Conflict of interest:** None

## INTRODUCTION

Osteoid osteoma is a slow-growing, benign osteogenic tumor first described by Bergstrand in 1930 and later recognized as an entity by Jaffe in 1935, rarely involving the craniofacial bones. They are benign osteogenic lesions characterized by compact and cancellous bone, a combination of both bone proliferation.<sup>1-6,8,9</sup> Earlier reports suggest an equal predilection for maxilla and mandible although they are slightly more in mandible.<sup>1,2</sup>

The etiology of these lesions largely remains unknown, but three theories have been proposed to explain the origin namely: Developmental, neoplastic, and reactive.<sup>3</sup> The incidence of occurrence of osteoma on the lower border of mandible and buccal aspect of mandible can be owed to reaction to trauma.<sup>4</sup> However, its occurrence in mandibular condyle is a rare entity. The objective of this study is to present the features of osteoid osteoma of the mandibular condyle.

## CASE REPORT

A 33-year-old male patient reported to the Oral and Maxillofacial Outpatient Department, Faculty of Dental Sciences (FODS), King George's Medical University, Lucknow with the chief complaint of progressive facial asymmetry and difficulty in speech and mastication for the past 6 months. Detailed history revealed that the patient had undergone a traumatic extraction of his right lower posterior tooth, and healing of the extraction site was uneventful. Two weeks following extraction, he started experiencing pain over the preauricular region on the same side. On clinical examination, there was gross facial asymmetry with deviation of mandible to the left side with shifting of the dental midline by 5 mm to the left side, reflecting an asymmetric prognathism (Fig. 1). Inter-incisal mouth opening was 30 mm. Lateral jaw movements were restricted with no obvious canting of occlusion, though an ipsilateral open bite and contralateral cross bite was evident.



**Fig. 1:** Gross facial asymmetry with deviation of jaw to the left side with swelling on the right side

<sup>1</sup>Associate Professor, <sup>2</sup>Professor, <sup>3,4</sup>Junior Resident

<sup>1-4</sup>Department of Oral and Maxillofacial Surgery, King George's Medical University, Lucknow, Uttar Pradesh, India

**Corresponding Author:** Debraj Howlader, Junior Resident Department of Oral and Maxillofacial Surgery, King George's Medical University, Lucknow, Uttar Pradesh, India, e-mail: drdebrajhowlader@gmail.com

The axial scan revealed an irregularly shaped right condylar head (Fig. 2). The 3D reconstructed and coronal computed tomography (CT) scans showed a pedunculated, well-defined, mushroom-like radiopaque mass with density similar to normal bone located on the medial aspect of the right mandibular condyle head (Figs 3 and 4). The condyle was enlarged and misshaped anteroposteriorly and mediolaterally.

All his blood parameters were within the normal limits, except for serum alkaline phosphatase level which was mildly elevated.

The patient underwent surgery under general anesthesia with fiber-optic nasotracheal intubation. Right Al-Kayat-Bramley incision (Fig. 5) was given to expose the temporomandibular junction. The morphology of the condylar head was misshaped on the lateral aspect. The tumor mass was attached on the medial aspect extending medially and superiorly toward the base of

the skull. The joint space was nonobliterated and was left unexplored. Right condylectomy was performed with safe margin of 0.5 mm. The tumor was detached from its soft tissue attachment, and osteotomy cut was given at the superior aspect of the neck of the condyle and removed along with condylar head (Fig. 4) and sent for histopathological analysis. The mass measured approximately 25 × 20 × 20 mm. The microscopic examination showed a number of irregular bone trabeculae and intervening fibro fatty marrow tissue. Central nidus of approximately 1.5 cm surrounded by a layer of dense woven bone was evident (Fig. 6). The nidus consisted of calcified osteoid lined with plump osteoblast in vascularized loose connective tissue.

The condylar position and occlusion were retained with positioned intermaxillary fixation for 3 weeks post-operatively followed with active physiotherapy, including lateral excursive, protrusive, and mouth opening.

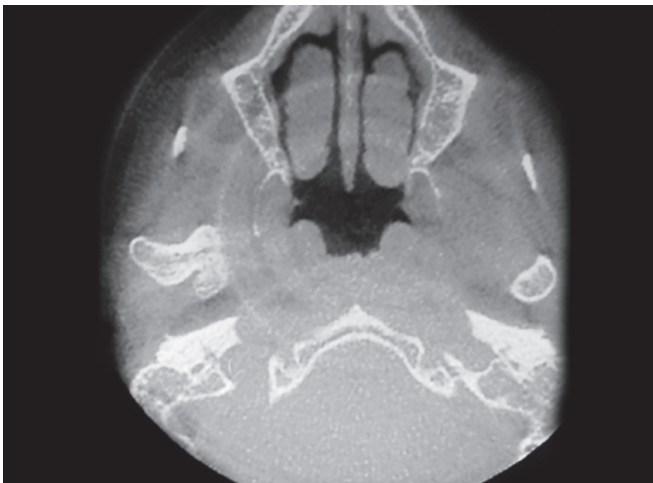


Fig. 2: Axial section of CT showing disfigured head of the right condyle

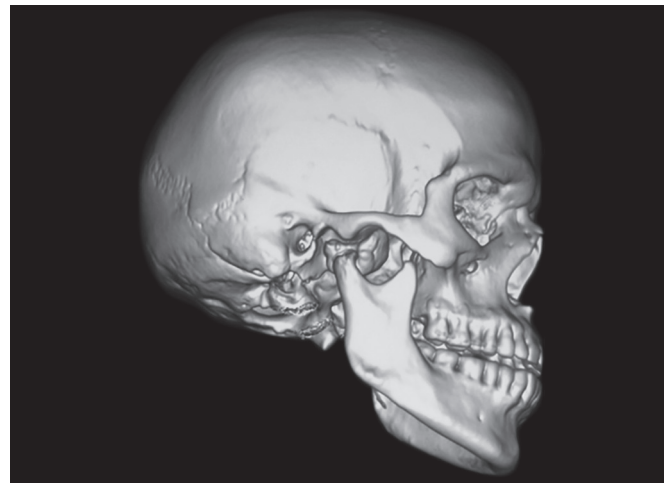


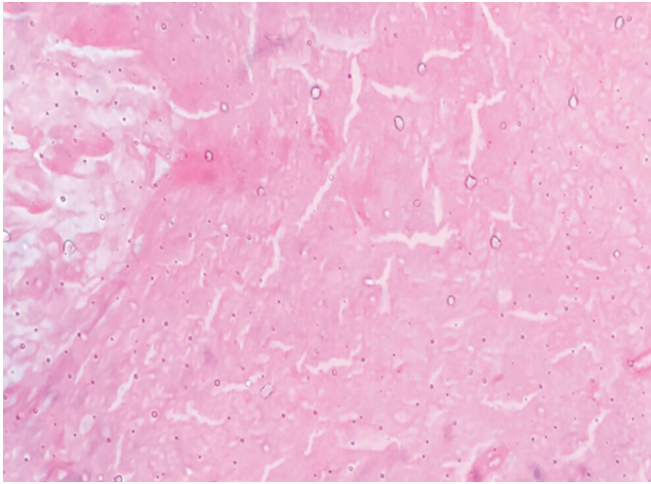
Fig. 3: Three-dimensional CT showing lesion on the medial aspect of right condylar head

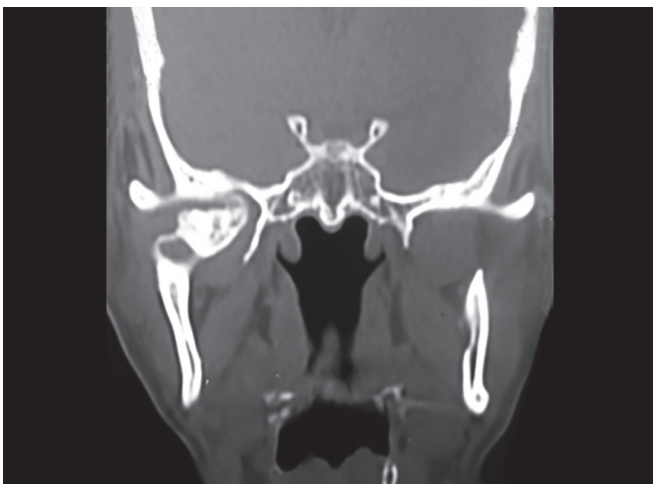

Fig. 4: Coronal view showing mushroom-like extension medially

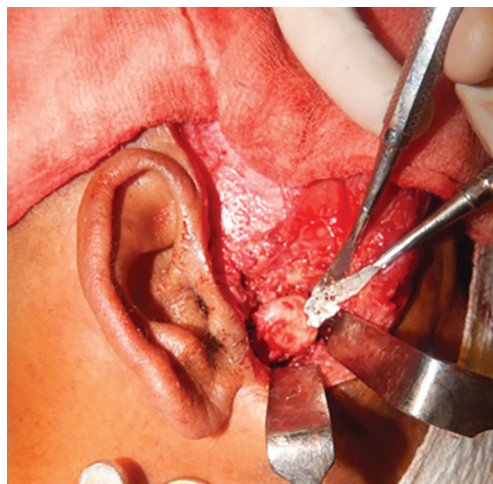

Fig. 5: Intraoperative picture of exposure of the tumor via Al-Kayat-Bramley incision



**Fig. 6:** High power microscopic view showing central nidus surrounded by mature lamellar bone

## DISCUSSION

Osteoid osteoma is a benign bone tumor characterized by small size, limited growth, and disproportionate pain. Pain is especially nocturnal with a duration of few weeks to a year, is experienced by patients prior to surgery, and hence, it shows marked response to nonsteroid anti-inflammatory drugs.<sup>5</sup> The very exact nature of pain and its nocturnal tendency cannot be fully understood. However, it is suggested that prostaglandins (especially PGE2) play a major role related to its presence in the nidus of the lesion.<sup>2,6</sup> However, in our case, there was no significant associated pain reported until gross asymmetry to the face was evident. Osteoid osteomas are common in the long bones and occur less than 1% in the jaws and its occurrence in mandibular condyle is additionally rare.<sup>7</sup> The lesion commonly affects the patient up to 2nd decade of life and is rarely seen in individuals over 30 years of age.<sup>1,2</sup> However, the age of our patient was 43 years.

The pathogenesis of osteoid osteoma has remained controversial. Some authors consider it as neoplasm while some like to believe it is mainly an inflammatory process. The precise nature is still unclear.<sup>8</sup>

Histologically, the characteristic feature of osteoma is a sclerotic bony margin, containing a central nidus. The lesion also contains vascularized, fibrous connective tissue with a small number of fibroblast. Multinucleated giant cells are rarely seen.<sup>2,6,9</sup> Our microscopic findings are in agreement with the literature. Osteoid osteoma is classified into three types according to the radiographic location of the nidus as cortical, cancellous, and subperiosteal. Cortical osteoid osteoma is the most common type and usually located within the center of the sclerosis. Cancellous osteoma accounts for one-fourth of the lesions and is located distant from mild to moderate osteosclerosis. The subperiosteal osteoma arises as a

soft tissue mass adjacent to affected bone and produces no active sclerosis.<sup>9</sup> An osteoid osteoma is better interpreted on CT than magnetic resonance imaging.<sup>9,10</sup> The nidus appears as well demarcated round or oval lesion of decreased attenuation on CT with variable amount of surrounding sclerosis and periosteal new bone. Punctate, amorphous, ring-like, dense, or smooth central mineralization are the different patterns that can be evident on the CT scans.<sup>5,10</sup>

In our case CT scans were useful to detect the number, size and location, areas of mineralization, sclerotic changes of the adjacent bone, and periosteal reaction. Although complete regression of the tumor have been reported by some author without any surgical intervention and no report of its malignant changes has been documented, surgeons prefer to excise the lesion.<sup>8</sup> Complete excision is currently the recommended treatment because it brings about immediate relief of pain and cures the diseases.<sup>1,2,8</sup> Osteoid osteoma does not usually recur after complete excision of the nidus. But may generally recur when there is incomplete excision or when there are multiple nidi.<sup>5</sup>

Differential diagnosis of the present case includes osteochondroma, ossifying fibroma, Paget's disease, sclerosing osteomyelitis, and osteoblastoma. Insignificant histopathological differences exist between osteoid osteoma and osteoblastoma. However, the latter has a greater growth potential, usually painless, and often shows enhanced radioopacities during radiological examination, whereas the nidus demarcates and is characteristic of osteoid osteoma.<sup>11,12</sup> Paget's disease is mostly seen in older patients affecting both maxilla and mandible.<sup>12</sup> Periosteal reaction and sclerotic changes may be radiographic finding of sclerosing osteomyelitis but the sequestrum of osteomyelitis is irregular rather than round and found in marrow spaces rather than cortical plates. No cellular atypia and multinucleated giant cells were seen in our microscopic findings, hence excluding compatibility with other similar lesions like osteosarcoma and giant cell lesions.

In conclusion, we present an unusual osteoid osteoma of mandibular condyle.

## REFERENCES

1. Klein, MJ.; Parisien, MV.; Schneider-Stock, R. Osteoid osteoma. In: Fletcher, DM; Unni, KK; Mertens, F, editors. WHO classification of tumors. Pathology and genetics: tumors of soft tissue and bone. Lyon: IARC Press; 2002. p. 260-261.
2. Chaudhary M, Kulkarni M. Osteoid osteoma of mandible. J Oral Maxillofac Pathol 2007 Jul;11(2):52-55.
3. Streitparth F, Teichgräber U, Walter T, Schaser KD, Gebauer B. Recurrent osteoid osteoma: interstitial laser ablation under



- magnetic resonance imaging guidance. *Skeletal Radiol* 2010 Nov;39(11):1131-1137.
4. Gupta OP, Jain RK, Agarwal MK, Khanna S, Shrivastava A. Osteoid osteoma of the mandible. *Ear Nose Throat J* 1986 Dec;65(12):574-575.
  5. Ida M, Kurabayashi T, Takahashi Y, Takagi M, Sasaki T. Osteoid osteoma in the mandible. *Dentomaxillofac Radiol* 2002 Nov;31(6):385-387.
  6. Yang C, Qiu WL. Osteoid osteoma of the eminence of the temporomandibular joint. *Br J Oral Maxillofac Surg* 2001 Oct;39(5):404-406.
  7. Karandikar S, Thakur G, Tijare M, Shreenivas K, Agrawal K. Osteoid osteoma of mandible. *BMJ Case Rep* 2011 Dec;11:1-4.
  8. Foss EL, Dockerty MB, Good CA. Osteoid osteoma of the mandible; report of a case. *Cancer* 1955 May-Jun;8(3):592-594.
  9. Kransdorf LT, Margaret AS, Fredrick WG, Richard PM. Osteoid osteoma. *Radiographics* 1991;11:671-696.
  10. Davies M, Cassar-Pullicino VN, Davies AM, McCall IW, Tyrrell PN. The diagnostic accuracy of MR imaging in osteoid osteoma. *Skeletal Radiol* 2002 Oct;31(10):559-569.
  11. Dunlop JA, Morton KS, Elliott GB. Recurrent osteoid osteoma. Report of a case with a review of the literature. *J Bone Joint Surg Br* 1970 Feb;52(1):128-133.
  12. Karunakaran K, Murugesan P, Rajeshwar G, Babu S. Paget's disease of the mandible. *J Oral Maxillofac Pathol* 2012 Jan;16(1): 107-109.