



## Neurilemmoma of Masseteric Space

<sup>1</sup>Admaja K Nair, <sup>2</sup>Twinkle S Prasad, <sup>3</sup>Valsa Thomas

### ABSTRACT

A neurilemmoma, also called schwannoma, is a benign, encapsulated, slow growing tumor arising from the neural sheath's Schwann cells of the peripheral, cranial or autonomic nerves. Clinically, a schwannoma is indistinguishable from other benign tumors. The etiology is unknown, there is no gender preference and the tumors occur most commonly between the ages of 20 and 50 years. Approximately 25 to 48% of these tumors occur in the head and neck region, with only 1% occurring in the mouth. The present article reports a case of masseteric space neurilemmoma, which demonstrates a remarkable presentation for this benign neural tumor.

**Keywords:** Schwannoma, Neurilemmoma, Tongue.

**How to cite this article:** Nair AK, Prasad TS, Thomas V. Neurilemmoma of Masseteric Space. *Oral Maxillofac Pathol J* 2014;5(1):445-448.

**Source of support:** Nil

**Conflict of interest:** None

### INTRODUCTION

Neurilemmoma is an encapsulated neoplasm composed of Schwann cells which can arise from any nerve covered with a Schwann cell sheath, which include the cranial nerves (except for the optic and olfactory), the spinal nerves, and the autonomic nervous system.<sup>1</sup> The cause of these neoplasm is unknown. It can be associated with von Recklinghausen disease; when this is the case, multiple tumors often are present. No racial or sex predilection is recognized. Neurilemmoma affect persons aged 20 to 50 years. Common locations for the tumors are, in order of decreasing frequency, the head and flexor surfaces of the upper and lower extremities and the trunk. About 25 to 48% of the lesions occur in the head and neck region. The frequencies of 16.9 and 22% for neurilemmoma were recorded in studies of the oral peripheral nerve sheath tumors.<sup>2,3</sup> In studies the most common site of intraoral schwannoma is base of tongue. Intraosseous variants are much more uncommon.

<sup>1</sup>Postgraduate Student, <sup>2</sup>Assistant Professor

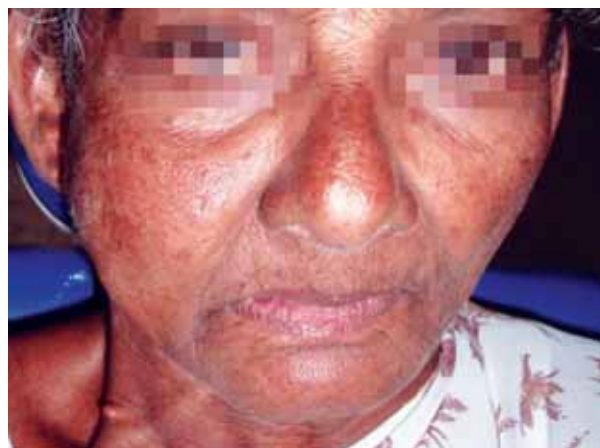<sup>3</sup>Professor and Head

<sup>1-3</sup>Department of Oral Medicine, Government Dental College Thiruvananthapuram, Kerala, India

**Corresponding Author:** Admaja K Nair, Postgraduate Student, Department of Oral Medicine, Government Dental College, Thiruvananthapuram, Kerala, India, Phone: 9961708559, e-mail: admajaknair@gmail.com

### CASE REPORT

A 64-year-old female patient reported with a swelling on right cheek since past 2 years which was gradually increasing in size. There was no pain, pus discharge, numbness or any other associated symptoms. Extraoral examination revealed asymmetry of the face due to swelling over right cheek. Well-defined swelling involving right side cheek of about 5 × 4 × 3 cm dimension and firm consistency, extending from right zygoma region inferiorly to the level of corner of mouth, medially involving buccal mucosa, anteriorly to level of nasolabial fold and laterally to the level of outer canthus of eye was noticed. Skin over the swelling appeared normal without any color change, ulceration or discharging sinuses. There was no functional impairment like difficulty in jaw movement, swallowing or speech. Intraorally the swelling involved entire right buccal mucosa, firm in consistency, nontender, regular, nonindurated and nonfluctuant. Buccal vestibular space was obliterated (Figs 1 and 2). The clinical diagnosis of benign connective tissue neoplasm was made. Panoramic radiography showed slight resorption in relation to edentulous alveolar ridge upper right maxilla (Fig. 3). CT maxilla plain sections showed a well-defined area of soft tissue density with multiple cystic spaces noticed along the right masseteric space of dimension 4.9 × 4.3 × 3.4 cm. There was remodeling of anterolateral border of right maxillary sinus and foramen rotundum and pterygopalatine foramen appeared widened. The lesion was abutting the masseter and lateral pterygoid muscles. Superiorly the lesion extended up to floor of orbit.



**Fig. 1:** Well-defined swelling over right side cheek

There was mild heterogeneous enhancement on contrast administration (Figs 4A to B). CT was suggestive of a benign neurogenic tumor possibly cystic schwannoma, and in differential diagnosis minor salivary gland tumor was also considered. Incision biopsy and ultrasound guided FNAC was inconclusive and excision was done under GA. Histopathological examination showed moderately

collagenous connective tissue stroma exhibiting neuritis, in Antoni type B pattern. Verocay bodies and areas of microcyst formation also were noticed (Figs 5A to 6B). There was minimal inflammation and moderate vascularity.

## DISCUSSION

Peripheral nerve tumors are uncommon entities in oral cavity. Schwannoma (Neurilemmoma) is a benign nerve sheath tumor that is composed entirely of well-differentiated Schwann cells. Neurilemmoma was first described by Verocay in 1910. He called it 'Neurinoma' then. In 1935, the term 'Neurilemmoma' was coined by Stout.<sup>4</sup> Two types is distinguished: central or peripheral schwannoma, located in bone or in soft tissues respectively. The etiology of the schwannoma is unknown. It is believed to originate from a proliferation of Schwann cells in the perineurium causing displacement and compression of the adjacent nerve.<sup>5</sup> Schwannoma can vary from small to considerable sizes. They account for only 1% of all the benign tumors in the oropharynx and in the oral cavity with the tongue, palate, cheek mucosa, lip and gingiva being the most frequent locations in the oral cavity. Clinically, two forms of oral schwannoma can occur: the most frequent is the encapsulated in which the tumor is surrounded by dense fibrous connective tissue; the other is pediculate, resembling a fibroma.<sup>6</sup> They are often seen in the 2nd and 3rd decades of life, and are very rare below 10 years of age, with no gender predilection. Neurilemmoma may occur at any age but are common between the ages of 20 and 50 years. The mobile portion, such as the dorsum, of the tongue is the

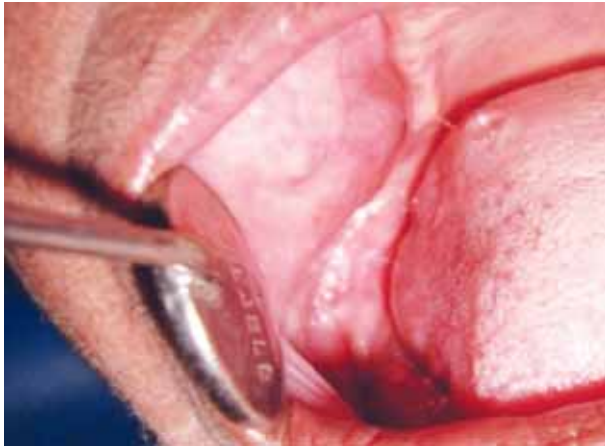

Fig. 2: Swelling involving entire buccal mucosa

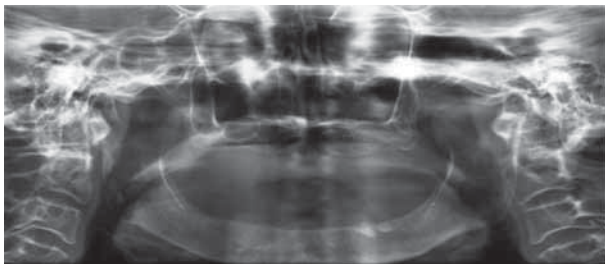
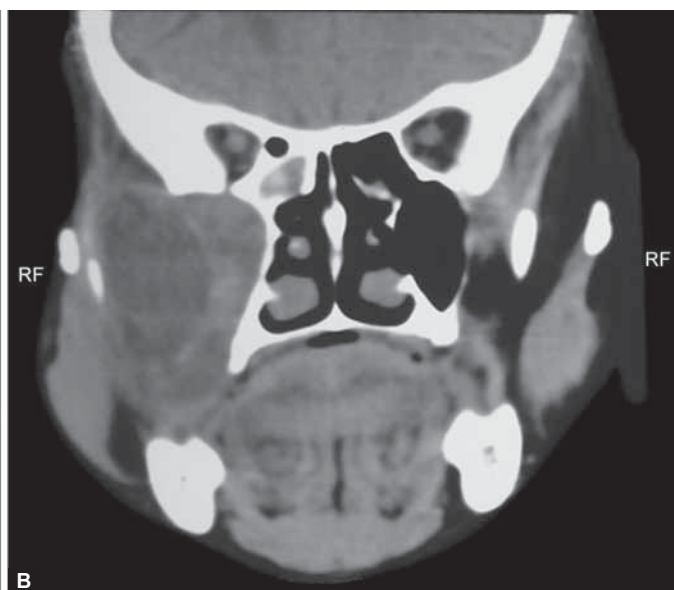
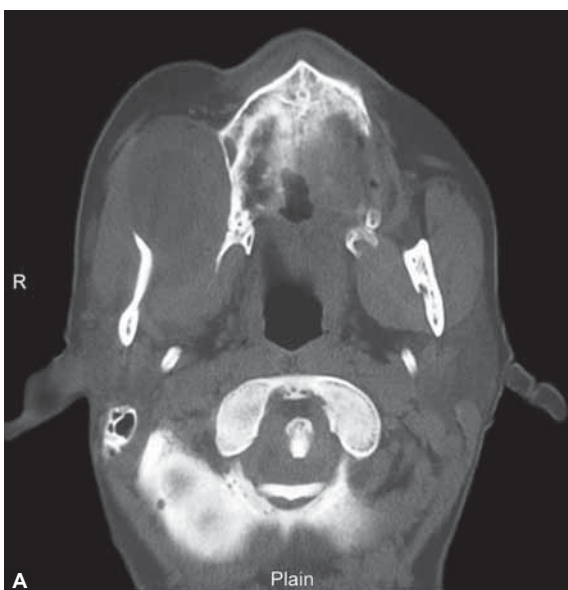
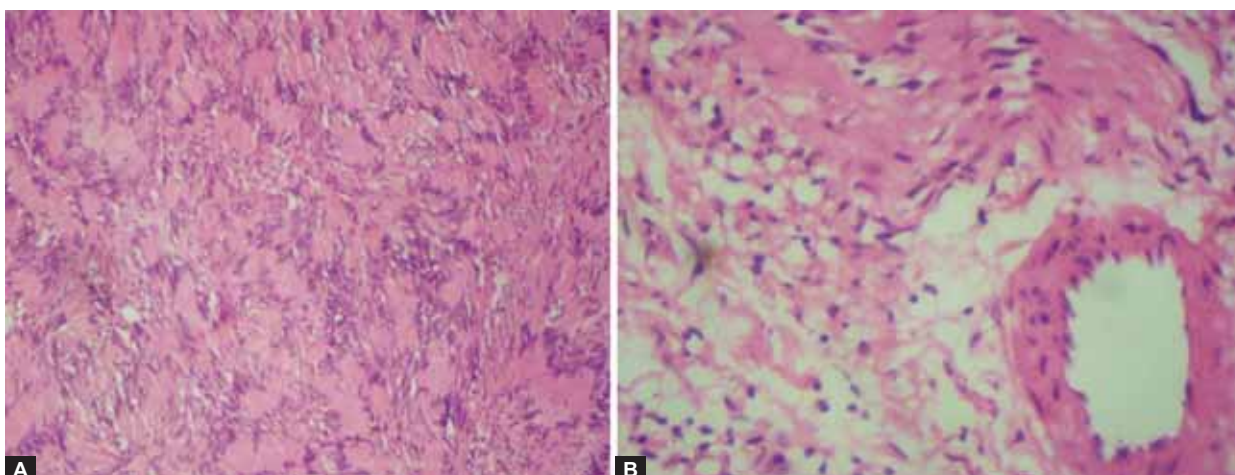


Fig. 3: Panoramic view with resorption of right upper alveolar ridge

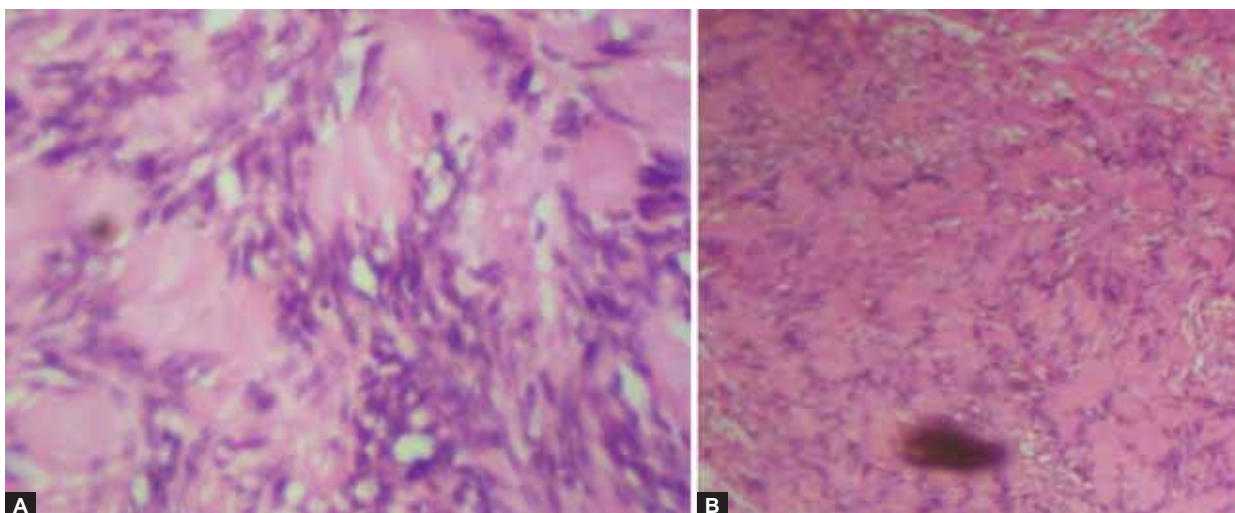


Figs 4A and B: Axial and coronal CT sections demonstrating extend of the lesion





**Figs 5A and B:** Photomicrograph showing antoni type A and B pattern and microcysts



**Figs 6A and B:** Histopathological appearance of schwannoma

most commonly affected site, but the base of the tongue is rare.<sup>7</sup> usually it is having unilobular growth pattern and rarely multilobular. It is usually a solitary lesion, slow growing and painless and can cause pressure on adjacent structures and clinically difficult to distinguish from other benign connective tissue tumors. The differential diagnosis includes malignant tumors, inflammatory and cystic lesions and numerous benign epithelial and connective tissue tumors (i.e. lipoma, traumatic fibroma, leiomyoma, granular cell tumor, neuroma and adenoma). The risk of malignant transformation is 8 to 10 %. The best imaging modality is MRI which should reveal a well-defined nodule with homogeneous hyper intense signal on T2-weighted and isointense to muscle on T1-weighted images.<sup>8</sup>

Microscopically the tumor is characterized with variable proportion of so-called Antoni A (spindle cells with their nuclei arranged in rows and displaying a palisading

effect, and with Verocay bodies which represent acellular zones) and Antoni type B (less cellular and less organized nonorganic areas) zones.<sup>9,10</sup> Specific diagnosis is by an immunohistochemical staining of S-100 for suspected tumors of neural origin because S-100 protein is positive in all neural tumors.

Surgical excision or enucleation is the treatment of choice. The prognosis is excellent, as malignant transformation and recurrence are rare after the complete resection.

## CONCLUSION

This case was worth reporting, as it denoted an unusual representation of neurilemmoma. When CT demonstrate cystic properties in soft tissues masses, oral and maxillofacial radiologists should consider schwannoma, based on a knowledge of the anatomy and physical characteristics of nearby nerves as in our case.

## REFERENCES

1. Zachariades N. Schwannoma of the oral cavity: review of the literature and report of a case. *J Oral Med* 1984;39:41-43.
2. Katz AD, Passy V, Kaplan N. Neurogenous neoplasms of major nerves of head and neck. *Arch Surg* 1971;103:51-56.
3. Lopez JI, Ballestein C. Intraoral schwannoma: a clinicopathologic and immunohistochemical study of nine cases. *Arch Anat Cytol Pathol* 1993;41:18-23.
4. Chrysomali E, Papanicolaou SI, Dekker NP, Regezi JA. Benign neural tumors of the oral cavity. *Oral Surg Oral Med Oral Path Oral Radiol Endod* 1997;84:381-390.
5. Artzi Z, Taicher S, Nass D. Neurilemmoma of the mental nerve. *J Oral Maxillofac Surg* 1991;49:196-200.
6. Hribernik SJ, Gould AR, Alpert B, Jones JL. Well-circumscribed mass of the lateral floor of the mouth. *J Oral Maxillofac Surg* 1992;50:741-746.
7. Wiess SW, Goldblum JR. Benign tumors of peripheral nerves. In: Enzinger FM, Weiss SW, editors. *Soft tissue tumors*. 4th ed. St. Louis, Mo: Mosby Year Book 2001:1111-1207.
8. Enoz M, Suoglu Y, Ilhan R. Lingual schwannoma. *J Cancer Res Ther* 2006;2:76-78.
9. Lacerda AS, Brentegani LG, Rosa AL, Vespucio MVO, Salata LA. Intraosseous schwannoma of mandibular symphysis: Case report. *Braz Dent J* 2006;17:255-258.
10. Shafer, Hine, Levy. *A Textbook of Oral Pathology*. 4th ed. India: Saunders; 2002. p.208.