

Clarified Butter as Xylene Substitute in Routine Histopathology of Oral and Maxillofacial Biopsies

Casilda Sushanthi.L

ABSTRACT

Introduction: An ideal clearing agent should remove alcohol from the tissue specimens to enable the penetration of paraffin wax which provides sturdiness to the tissue specimen. Xylene has toxic effects and is still used because of its accurate clearing property and maintaining the staining quality. Natural alternatives to xylene provide a less toxic environment for histopathological technicians.

Aim: The study is to evaluate the accuracy of clarified butter as xylene substitute in routine histopathological tissue processing procedure.

Materials and Methods: 40 paired soft tissue specimens were obtained from the Department of Oral pathology and microbiology and subjected to routine histopathological tissue processing with xylene and ghee as clearing agents. Post processing, the tissue specimens were immersed in paraffin wax overnight, embedded, sectioned and stained using hematoxylin and eosin. Histopathological criteria namely nuclear staining, cytoplasmic staining, artefacts and background staining were evaluated and the scores were tabulated and statistical analysis was done using SPSS version 20 by IBM.

Results: Our study results showed that tissue specimens processed in xylene and ghee had similar nuclear staining. In cytoplasmic staining, tissue specimens processed in ghee had superior results than xylene processing. Artefacts were present more in xylene processing than ghee processing. Background staining was more appreciated in xylene processed tissue specimens than ghee processing.

Conclusion: Substituting xylene with ghee showed better results as a clearing agent in routine histopathological tissue processing. Ghee as a clearing agent is non toxic, cost effective compared to xylene and a safer alternative.

Keywords: Natural alternative, xylene, Clarified butter, Histopathological laboratory
Oral and Maxillofacial Pathology Journal (2023): <https://www.ompj.org/archives>

INTRODUCTION

Clearing of tissues is the most delicate step in diagnostic pathology. An ideal clearing agent should induce rapid removal of dehydrant, it should be easily replaced with paraffin wax and should have low toxicity. It acts as a transitional procedure from dehydration to infiltration. Clearing process plays a crucial role by ensuring maximum removal of the dehydrant (alcohol) from the tissues, making the tissues transparent which in turn enables high levels of penetration of paraffin wax.¹ Xylene is an aromatic hydrocarbon widely used in medical field and in dentistry, xylene is traditionally a popularly used tissue clearing agent due to its rapid clearing capacity and miscibility with most organic solvents. Xylene also has excellent dewaxing and clearing properties in staining procedures and remains as a gold standard procedure for clearing in tissue processing procedure. Xylene used in laboratories are mainly composed of composed of m-xylene (40–65%), p-xylene (20%), o-xylene (20%) and ethyl benzene (6–20%) and traces of toluene, trimethyl benzene, phenol, thiophene, pyridine and hydrogen sulfide.² The permissible exposure limit for xylene is 100ppm as an 8 hour time weighted average concentration by Occupational Safety and Health Administration.³ Histopathology technicians and

Department of Oral and Maxillofacial Pathology, Saveetha Dental College and Hospitals, Saveetha Institute of Medical and Technical Sciences, Chennai-77, India.

Corresponding author: Casilda Sushanthi.L, Department of Oral and Maxillofacial Pathology, Saveetha Dental College and Hospitals, Saveetha Institute of Medical and Technical Sciences, Chennai-77, India. Email : dr.casilda@gmail.com

How to cite this article: Sushanthi CL. Clarified Butter as xylene Substitute in Routine Histopathology of Oral and Maxillofacial Biopsies. Oral Maxillofac Pathol J.2023;14(1): page number 49-55

Source of Support: Nil

Conflict of Interest: None

oral pathologists when exposed to xylene vapours in the workplace might have higher incidence of kidney, lung, eyes and central nervous system related diseases. It is a flammable liquid and may cause over hardening of the tissues when exposed for longer durations. As a result of increasing concerns about the potential carcinogenicity of the chemical agents used in routine tissue processing, implementing eco-friendly chemical agents is necessary. Substitution of an element means replacing or finding a substance that can

perform the same function which may lessen the hazards. Ghee is a class of clarified butter that originated in ancient India. It is commonly used in middle-eastern cuisine, Indian Cuisine, as a traditional medicine and in religious rituals. Cow milk is the main source for ghee. Ghee derived from cow milk contains hundreds of fatty acids. The main composition of Cow milk derived ghee includes Fats, Saturated fats, Proteins, Mono unsaturated fatty acid, polyunsaturated fatty acid and trans-fat. Ghee is a complex structure of lipids (mainly triglycerides), free fatty acids, phospholipids, fat soluble vitamins, hydrocarbons and carotenoids. This high fat content of ghee helps in clearing of tissues without altering the morphology or histological structure of the tissue. In an effort to improve working conditions in the histopathologic laboratory, we have investigated whether less toxic substance like ghee/Clarified butter may be substituted for toxic organic solvent like xylene, which is currently in use.

MATERIALS AND METHODS

Sample Selection: The present study was carried out in the Department of Oral and Maxillofacial Pathology, Saveetha Dental College and Hospitals, Chennai. The study was approved by the Institutional Review Board. We prepared 40 paired soft tissue specimens for routine histopathological evaluation using xylene (Group A) and Clarified Butter (Group B) as Clearing agents. The specimens fall under the 4 categories of i) mucosa ii) adipose tissue iii) muscle and iv) gland

Histopathology Processing:

The Department has a pre-established in-house xylene processing. The methodology is as follows. Post fixation and measurements of the gross specimen, the tissue specimens were placed in cassettes and processed as described in Table 1. The reagents for histopathological processing were manufactured by MERCK. Ghee which is a cow milk derivative was purchased from the local commercial market. Thymol, a component of thyme oil was added to ghee which acts as a disinfectant. The

impregnated tissues were embedded and tissue sections of 3 micrometre were made using semi-automated tissue rotary microtome by Leica (RM-2245), Germany. Tissue sections were later stained with hematoxylin and eosin stain to assess tissue morphology.

Evaluation of tissue Sections: The paired tissue samples were evaluated by 2 independent Oral Pathologists blinded to the type of Processing. The staining efficacy, morphological characteristics, background staining and artifacts were scored. The scoring criteria were as follows. It was evaluated with histomorphologic criteria such as nuclear staining, cytoplasmic staining, background staining and artifacts by two independent Oral Pathologists. The histomorphologic criteria were graded with a score of 1-4 for nuclear staining and cytoplasmic staining, 0-3 for background staining and 0-1 for artefacts (Table 2).

Statistical analysis:

Percentage adequacy of clearing between ghee and xylene was compared using Mann Whitney U test. (Kappa statistics not performed) Within group comparisons was done using Pearson Chi-square tests. p value <0.05 was considered to be statistically significant. Comparison between xylene and ghee processed tissue specimens within the subcategories was done by using Krusal Wallis Anova. The scores obtained were tabulated and assessed for the statistical significance using SPSS version 20 by IBM.

RESULTS

The percentage of adequacy for the parameters for 40 tissue samples analysed between xylene(20 tissue samples) and ghee (20 tissue samples) for the four different tissue types was calculated. Excellent nuclear staining was noted in 35% of sections in both xylene and ghee Processing. 2.5% of the xylene processed tissues had poor nuclear staining whereas none (0%) of the Clarified butter processed specimens had poor nuclear staining. Clarified butter processed specimens had relatively better nuclear staining than xylene processed tissues (Figure 1) [U=199, p=0.973].

Table 1: Pre-established in-house methodology for histopathological processing of gross specimens. It is an in-house (patented) tissue processing procedure. As the title reads the main aim of the study is to switch xylene with Clarified butter, hence the other tissue processing methods remain the same.

Procedure	Xylene processing			Clarified butter processing		
	Solution	Temperature	Time	Solution	Temperature	Time
Fixation	10% formalin	37 degree C	24 hrs	10% formalin	37 degree C	24 hrs
Dehydration	Isopropyl alcohol	50 degree C	30 mins	Isopropyl alcohol	50 degree C	30 mins
Dehydration	Acetone	50 degree C	30 mins (2 changes)	Acetone	50 degree C	30 mins (2 changes)
Clearing	Xylene	50 degree C	30 mins (2 changes)	Ghee/ Clarified butter	50 degree C	35 mins (2 changes)
Wax impregnation	Paraffin wax	50 degree C	1 overnight	Paraffin wax	50 degree C	1 overnight

Table 2: Scores graded for histomorphologic criteria of 40 tissue specimens

Histomorphologic criteria	Scoring
hi) Nuclear staining ii) Cytoplasmic staining	1- poor
	2- fair
	3- good
	4- excellent
iii) Background staining	0-nil
	1-mild
	2-moderate
	3-severe
iv) Artefacts	0-no
	1-yes

25% of the Clarified butter processed specimens had excellent cytoplasmic staining and 0% had poor staining. On the other hand, only 22.5% of the xylene processed specimens had excellent cytoplasmic staining. 2.5% of the specimens also had poor cytoplasmic staining. However, there was no statistically significant difference in the cytoplasmic staining between xylene and ghee processed specimens (Figure 2) [U=190, p=0.768]. Artefacts were present in 27.5% of xylene processed samples as against 22.5% of ghee processed samples. Though samples processed with Clarified butter had less artefacts, the difference was not found to be statistically significant (Figure 3) [U=180, p=0.532]. Background staining was seen in 27.5% of xylene processed samples as against 22.5% of ghee processed samples (Figure 4) [U=197, p=0.93]. 2.5% of ghee processed specimens also had severe background staining. Pair wise percentage comparison of the parameters nuclear staining (Table 3), cytoplasmic staining (Table 4), background staining (Table 5) between xylene processing

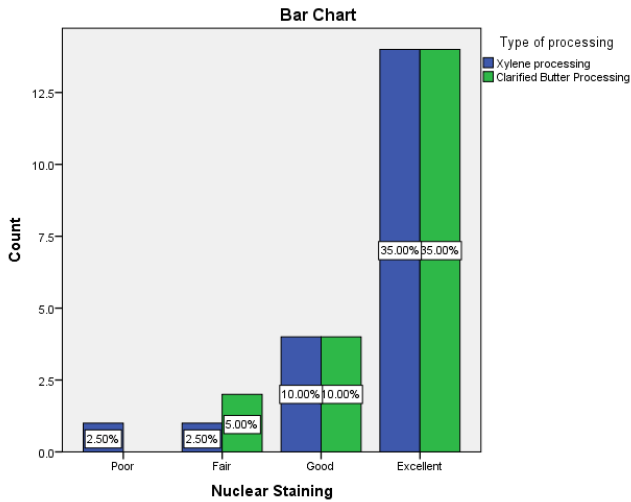


Fig. 1: Comparison of nuclear staining between xylene and Ghee processed tissue specimens

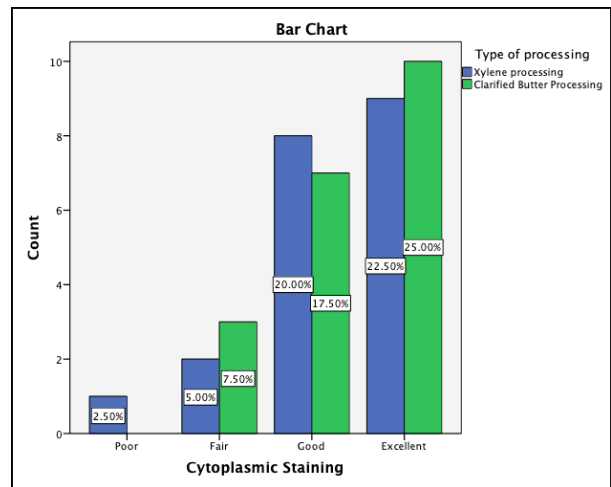


Fig. 2: Comparison of cytoplasmic staining between xylene and Ghee processed tissue specimens

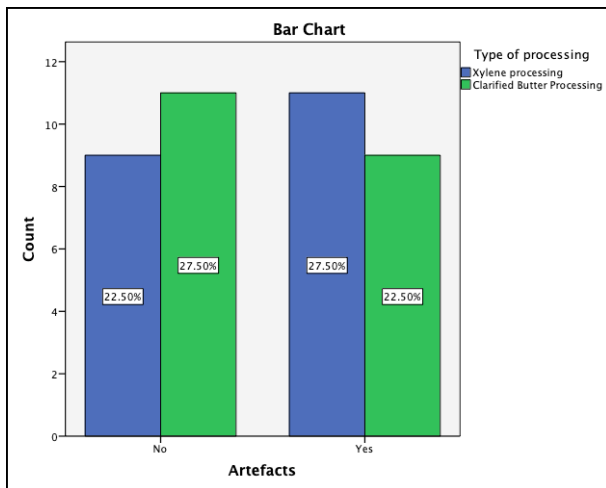


Fig. 3: Comparison of artefacts seen in tissue specimens processed by xylene and Ghee.

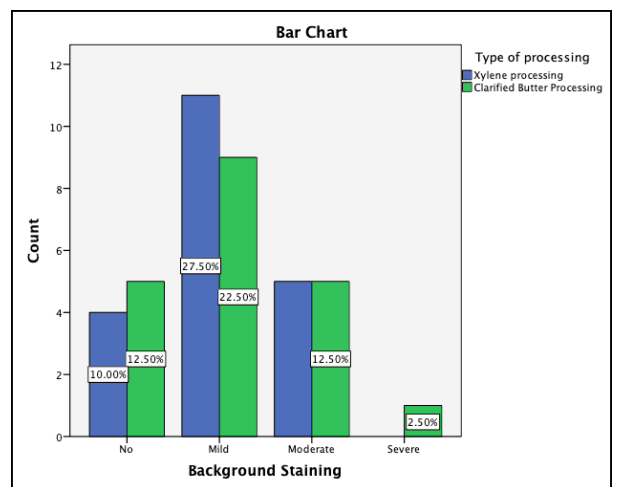


Fig. 4: Comparison of background staining seen in tissue specimens processed by xylene and Ghee.

and ghee processing are summarized below. Comparison of the histopathological parameters between xylene processed and ghee processed Specimens are summarized in Table 6. Comparison of the histopathological parameters between xylene processed and ghee processed Specimens within the subcategories are summarized in Table 7, Table 8, Table 9 and Table 10 respectively.

DISCUSSION

Clearing of tissue specimens is a crucial process in tissue

processing prior to sectioning and staining. Conventionally xylene has been employed as the clearing agent in histopathology labs. Other xylene alternatives like coconut oil, Olive oil have been tried previously.⁴ The present study using ghee/clarified butter is an innovative attempt and a novel study with no pre-existing literature on the usage of ghee as a xylene substitute. 20 matched Tissue specimens from four different tissue types were selected to assess ghee as a xylene substitute. The clearing process makes the tissue transparent and the clarity achieved after the clearing process is crucial to arrive

Table 3: Adequacy of nuclear staining between xylene and Ghee processed tissue specimens in four categories

Nuclear Staining								
	Ghee Processing				Xylene Processing			
Score	Muscle	Gland	Adipose Tissue	Mucosa	Muscle	Gland	Adipose Tissue	Mucosa
0	0%	0%	0%	0%	0%	0%	0%	0%
1	0%	0%	0%	0%	20%	0%	0%	0%
2	0%	0%	40%	0%	20%	0%	0%	0%
3	0%	20%	60%	0%	20%	0%	60%	0%
4	100%	80%	0%	100%	40%	100%	40%	100%

Table 4: Adequacy of cytoplasmic staining between xylene and Ghee processed tissue specimens in four categories

Cytoplasmic Staining								
	Ghee Processing				Xylene Processing			
Score	Muscle	Gland	Adipose Tissue	Mucosa	Muscle	Gland	Adipose Tissue	Mucosa
0	0%	0%	0%	0%	0%	0%	0%	0%
1	0%	0%	0%	0%	20%	0%	0%	0%
2	20%	20%	20%	0%	20%	0%	20%	0%
3	40%	0%	60%	40%	60%	40%	40%	20%
4	40%	80%	20%	60%	0%	60%	40%	80%

Table 5: Adequacy of background staining between xylene and Ghee processed tissue specimens in four categories

Background Staining								
	Ghee Processing				Xylene Processing			
Score	Muscle	Gland	Adipose Tissue	Mucosa	Muscle	Gland	Adipose Tissue	Mucosa
0	40%	80%	0%	80%	40%	60%	00%	80%
1	60%	20%	100%	20%	60%	40%	100%	20%
2	0%	0%	0%	0%	0%	0%	0%	0%
3	0%	0%	0%	0%	0%	0%	0%	0%
4	0%	0%	0%	0%	0%	0%	0%	0%



at a diagnosis.⁵ Tissue specimens processed in ghee showed similar results as xylene processing in nuclear staining. As far as cytoplasmic staining was concerned, tissue specimens processed in ghee showed superior results compared to routine xylene processing. This finding is in accordance with

the literature by Ramamoorthy et al who stated that coconut oil, cedarwood oil and bleached palm oil can be used as xylene alternatives. As reported by Ramamoorthy et al, Coconut oil as a clearing agent showed good clearing accuracy because of its high saturated fat content.⁶ Ghee also contains high fat content

Table 6: Comparison of the histopathological parameters between xylene processed and Ghee processed Specimens

Type of processing		N	Mean Rank	Sum of Ranks	Mann Whitney U	P value
Nuclear Staining	Xylene processing	20	20.45	409.00	199.000	.973
	Clarified Butter Processing	20	20.55	411.00		
Cytoplasmic Staining	Xylene processing	20	20.00	400.00	190.000	.768
	Clarified Butter Processing	20	21.00	420.00		
Artefacts	Xylene processing	20	21.50	430.00	180.000	.532
	Clarified Butter Processing	20	19.50	390.00		
Background Staining	Xylene processing	20	20.35	407.00	197.000	.930
	Clarified Butter Processing	20	20.65	413.00		

Table 7: Comparison of the histopathological parameters between xylene processed and Ghee processed Specimens in the subcategory-Muscle.

Tissue	Parameter	Type of processing	N	Mean	P value
Muscle	Cytoplasmic staining	Xyleneprocessing	5	4.30	.178
		Clarified butter processing	5	6.70	
	Nuclear staining	Xyleneprocessing	5	4.00	.054
		Clarified butter processing	5	7.00	
	Artefacts	Xyleneprocessing	5	5.50	1.000
		Clarified butter processing	5	5.50	
	Background staining	Xyleneprocessing	5	5.60	.910
		Clarified butter processing	5	5.50	

Table 8: Comparison of the histopathological parameters between xylene processed and Ghee processed Specimens in the subcategory-Gland.

Tissue	Parameter	Type of processing	N	Mean	P value
Gland	Cytoplasmic Staining	Xyleneprocessing	5	5.20	.699
		Clarified butter processing	5	5.80	
	Nuclear Staining	Xyleneprocessing	5	6.00	.317
		Clarified butter processing	5	5.00	
	Artefacts	Xyleneprocessing	5	6.00	.513
		Clarified butter processing	5	5.00	
	Background Staining	Xyleneprocessing	5	5.50	1.000
		Clarified butter processing	5	5.50	

which makes it heat stable with better penetrability into the tissues.

Artefacts were present in similar ratios in tissue specimens processed in both ghee and xylene. Mild background staining was more appreciated in tissue specimens processed by xylene compared to ghee processing. This finding proves that ghee has superior clearing accuracy compared to xylene by maintaining the tissue architecture of the specimen. The tissue specimens were stained using hematoxylin and eosin stains and the quality of stain retainment in ghee processed tissues were similar to xylene processed tissue specimens even after 4 months. It was found that the mean rank for nuclear staining, cytoplasmic staining, artefacts and background staining between ghee and xylene showed higher values for ghee processing. Yet, ghee processed tissue specimens showed similar and superior results than xylene processed tissue specimens in terms of clearing accuracy and maintaining the staining quality. The staining of samples processed by ghee was superior to that of

xylene although the difference was not statistically significant.

Xylene is a universal gold standard clearing agent widely used in histopathological laboratories for tissue processing in the last few decades.⁷ Xylene exposure occurs by inhalation of xylene vapours, ingestion or by eye or skin contact. Xylene is primarily metabolised in the liver and excreted in urine. Xylene has non cancerous effect but chronic exposure to xylene vapours or direct contact with xylene can lead to blood toxicity.⁸ Xylene is considered to be the safest alternative to benzene and chloroform since the 1950s. In the late 1970s it was discovered that neurotoxicity caused by xylene was greater than other chemical reagents. Xylene is inflammable and its vapours are irritable on skin and might cause drying, scaling and acute infections. Tissue specimens immersed in xylene for longer durations result in tissue distortion. Disposal of xylene in laboratories is another major problem. Despite the drawbacks, xylene is still widely used in histopathological

Table 9: Comparison of the histopathological parameters between xylene processed and Ghee processed Specimens in the subcategory-Adipose tissue.

Tissue	Parameter	Type of processing	N	Mean	P value
Adipose tissue	Cytoplasmic Staining	Xyleneprocessing	5	5.90	.650
		Clarified butter processing	5	5.10	
	Nuclear Staining	Xyleneprocessing	5	7.10	.058
		Clarified butter processing	5	3.90	
	Artefacts	Xyleneprocessing	5	5.50	1.000
		Clarified butter processing	5	5.50	
	Background Staining	Xyleneprocessing	5	6.00	.549
		Clarified butter processing	5	5.00	

Table 10: Comparison of the histopathological parameters between xylene processed and Ghee processed Specimens in the subcategory-Mucosa

Tissue	Parameter	Type of processing	N	Mean	P value
Mucosa	Cytoplasmic staining	Xyleneprocessing	5	6.00	.513
		Clarified butter processing	5	5.00	
	Nuclear staining	Xyleneprocessing	5	5.50	1.000
		Clarified butter processing	5	5.50	
	Artefacts	Xyleneprocessing	5	6.00	.317
		Clarified butter processing	5	5.00	
	Background staining	Xyleneprocessing	5	4.70	.343
		Clarified butter processing	5	6.30	



labs as a clearing agent in clearing and staining procedure because of its accuracy, rapid action potential, maintaining staining quality, low economic cost and easy availability in the market.⁹ Considering the health hazards associated with xylene exposure, it has become mandatory to use a lesser toxic alternative to xylene. From the present study it is evident that ghee serves as a potential xylene substitute and may be used as a clearing agent for processing tissue samples.

The authors do acknowledge the presence of limitations of the study like smaller sample size. Samples from only four different soft tissue types were selected and more tissue types should be selected to evaluate the accuracy of ghee as a clearing agent for wider applications in other anatomic sites. The number of changes of ghee required after each processing cycle was not noted. Since it has high fat content, it tends to crystallize in humid weathers that has to be addressed.

CONCLUSION

The present study proves that ghee/Clarified butter is equivalent and superior to xylene in routine histopathological tissue processing procedure. Ghee is a nontoxic, bio-friendly, cost effective, easily available and safer alternative to xylene in processing surgical pathology specimens. Substituting xylene with natural alternatives will provide a favourable laboratory environment for histopathology technicians and oral pathologists. Ghee/Clarified butter can be a safety milestone to advance the field of histopathology.

REFERENCES

1. Dineshshankar J, Saranya M, Tamilthangam P, Swathiraman J, Shanmathee K, Preethi R. Kerosene as an Alternative to xylene in Histopathological Tissue Processing and Staining: An Experimental Study. *J PharmBioallied Sci.* 2019 May;11(Suppl 2):S376-9.
2. Kandyala R, Raghavendra SPC, Rajasekharan ST. Xylene: An overview of its health hazards and preventive measures. *J Oral MaxillofacPathol.* 2010 Jan;14(1):1-5.
3. Occupational Safety and Health Administr. OSHA Technical Manual. Government Institutes; 1999. 474 p.
4. Swamy SRG, Nandan SRK, Kulkarni PG, Rao TM, Palakurthy P. Bio-Friendly Alternatives for Xylene - Carrot oil, Olive oil, Pine oil, Rose oil. *J ClinDiagn Res.* 2015 Nov;9(11):ZC16-8.
5. Ankle M, Joshi P. A study to evaluate the efficacy of xylene-free hematoxylin and eosin staining procedure as compared to the conventional hematoxylin and eosin staining: An experimental study [Internet]. Vol. 15, *Journal of Oral and Maxillofacial Pathology.* 2011. p. 161. Available from: <http://dx.doi.org/10.4103/0973-029x.84482>
6. Ramamoorthy A, Ravi S, Jeddy N, Thangavelu R, Janardhanan S. Natural Alternatives for Chemicals Used in Histopathology Lab- A Literature Review. *J ClinDiagn Res.* 2016 Nov;10(11):EE01-4.
7. Sravya T, Rao GV, Kumari MG, Sagar YV, Sivaranjani Y, Sudheerkanth K. Evaluation of biosafe alternatives as xylene substitutes in hematoxylin and eosin staining procedure: A comparative pilot study. *J Oral MaxillofacPathol.* 2018 Jan;22(1):148.
8. Niaz K, Bahadar H, Maqbool F, Abdollahi M. A review of environmental and occupational exposure to xylene and its health concerns. *EXCLI J.* 2015 Nov 23;14:1167-86.
9. Shah AA, Kulkarni D, Ingale Y, Koshy AV, Bhagalia S, Bomble N. Kerosene: Contributing agent to xylene as a clearing agent in tissue processing. *J Oral MaxillofacPathol.* 2017 Sep;21(3):367-74.

