

Soft tissue sarcoma of skeletal muscle origin from an oral and maxillofacial pathologist perspective in relation to head and neck region of children – A Systematic Review

Sai Sudha Muddha¹, P.Subhashini¹, A. Senthil Kumar², Karthik Shunmugavelu³, Barun Kumar⁴, Karthi Kumar Murari⁵

ABSTRACT

Introduction: Mesenchymal cell origin tumour with malignant nature, rhabdomyosarcoma, a sarcoma of solid tumour type in paediatric population, presents different varied muscle cells architecture in the oral and maxillofacial region. Immunohistochemistry plays a pivotal role in the differentiation of rhabdomyosarcoma from other soft tissue tumours of paediatric population.

Materials and Methods: Major databases such as Medline were explored detailed literature search in resulting in a systematic review pertaining to immunohistochemistry of rhabdomyosarcoma especially in the oral and maxillofacial region of paediatric population, leading to determination of anatomy, classification, histopathology, age, gender and immunohistochemical markers.

Results: Seven original research scientific articles pertaining to the head and neck paediatric rhabdomyosarcoma were highlighted depicting heterogenous cellular features, which is to be confirmed by immunohistochemistry.

Conclusion: Histopathology plays an important role in the diagnosis of paediatric head and neck rhabdomyosarcoma whereas immunohistochemistry is the main differentiation factor in case of subtypes, nature, management and prognosis.

Keywords: Paediatric, rhabdomyosarcoma, head, neck, oral, maxillofacial, pathology, immunohistochemistry.

INTRODUCTION

A soft tissue malignant tumour of cellular diversity and variable cellular differentiation of muscle cells with mesenchymal cell origin denotes rhabdomyosarcoma (RMS), which accounts for approximately 5% of paediatric neoplasms of malignant nature. During first decade of life, identification of rhabdomyosarcomas account for more than 50%. The four main RMS subtypes are embryonal, alveolar, pleomorphic, and spindle/sclerosing RMS, as per World Health Organisation (WHO). Sites of occurrence are head, neck, extremities and genitourinary tract. Sites of involvement are orbit, middle ear, nasal cavity, paranasal sinuses, nasopharynx and infratemporal fossa, parameningeal, nonparameningeal in which parameningeal sites are those adjacent to meninges as nasal cavity, paranasal sinuses, nasopharynx, middle ear/mastoid, parapharyngeal space, infratemporal fossa and pterygopalatine fossa, oral cavity, oropharynx, face and cheek^{1,2,3,4,5}. The immunohistochemical reactions included vimentin, desmin and myogenin, Embryonal, alveolar and pleomorphic are the types of RMS. Classic, spindle cell and botryoid are the types of ERMS. Mesenchymal cells tend to differentiate into cross-striated muscle cells in ERMS, being a moderately cellular tumor with loose myxoid stroma with smaller sized cell nuclei. Two additional subtypes of embryonal rhabdomyosarcoma such as sarcoma botryoides and spindle cell rhabdomyosarcoma

¹Department of Pathology, Sree Balaji Medical College and Hospital Chrompet, Chennai, India; ²Department of Oral & Maxillofacial Surgery, Tamilnadu Government Dental College Hospital, Tamil Nadu, India; ³Department of Dentistry/Oral and Maxillofacial Pathology, PSP Medical College Hospital and Research Institute, Tambaram, Kanchipuram, Tamilnadu, India; ⁴Department of Oral and Maxillofacial Surgery, Bharati Vidyapeeth (Deemed to be University) Dental college and hospital, Navi Mumbai, India; ⁵Department of Dentistry, University of Science and Technology, Fujairah, United Arab Emirates.

Corresponding Author: Karthik Shunmugavelu, Department of Dentistry/Oral and Maxillofacial Pathology, PSP Medical College Hospital and Research Institute, Tambaram, Kanchipuram, Tamilnadu, India. E-mail: drkarthiks1981@gmail.com

How to cite the article: Muddha SS, Subhashini P, Senthil KA, Shunmugavelu K, Kumar B, Murari KK. Soft tissue sarcoma of skeletal muscle origin from an oral and maxillofacial pathologist perspective in relation to head and neck region of children – A Systematic Review. Oral Maxillofac Pathol J 2024; 15(2); 229-234.

Source of Support: Nil

Conflict of Interest: None

have been documented. Multimodal treatment with multi-agent chemotherapy, radiation and surgery confers the greatest chance for survival in the treatment of head and neck RMS. Li-Fraumeni syndrome (tumor protein p53

mutations), Beckwith-Wiedemann syndrome (11p15 defects), von Recklinghausen disease (neurofibromatosis type 1 mutations), cardiofaciocutaneous syndrome (B-Raf mutations) and Noonan syndrome [rat sarcoma (RAS)/mitogen-activated protein kinase signaling pathway mutations) are associated with RMS. Oncogenic mutations involving the anaplastic lymphoma kinase, RAS, fibroblast growth factor receptor 4, phosphatidylinositol-4,5-bisphosphate 3-kinase catalytic subunit alpha or catenin-cadherin-associated protein beta 1 genes gives rise to ERMS. Translocation between the forkhead box protein O1 transcription factor gene (which is located on

chromosome 13) and either the paired box (PAX)3 transcription factor gene on chromosome 2 or the PAX7 gene on chromosome 1, and mutations in the v-Myc avian myelocytomatosis viral oncogene neuroblastoma derived homolog and the c-Met genes gives rise to ARMS. Pleomorphic RMS occurs in both children and adults, with higher rates of recurrence and metastasis^{6,7,8}. The aim of this study was to review original research pertaining to rhabdomyosarcoma of head and neck region in paediatric population, which entails anatomy, classification, age, gender, clinical presentation, histopathology and immunohistochemistry.

Table 1 – Summary

Author	Type	Location	Age	Gender	Year	Immuno histochemistry
Mariana P Rodríguez-Vargas, Francisco G Villanueva-Sánchez	ERMS	mandible, maxilla, mastoid conjunctiva	1-13 years	males	2022	vimentin, desmin, myoglobin, and muscle specific actin, myogenin, MYO D1
JOANNA RADZIKOWSKA, WOJCIECH KUKWA, ANDRZEJ KUKWA, ANNA M. CZARNECKA, MACIEJ KAWECKI, FEI LIAN, CEZARY SZCZYLIK and ANTONI KRZESK	ARMS	parameningeal	2-13 years	males	2016	-
Cléverton Roberto de ANDRADE Ademar Takahama JUNIOR Inês Nobuko NISHIMOTO Luiz Paulo KOWALSKI Márcio Ajudarte LOPES	ERMS	Parameningeal orbit	14.3 years	-	2010	vimentin, desmin, myogenin, MyoD1, AE1/AE3, p53, PCNA, Ki67, C-erbB2, FAS and CDK4.
Atif Ali Ahmed, MD, and Maria Tsokos	SINON ASAL	Ethmoid, frontal, maxillary	9-11 years	females	2007	desmin and myogenin
H. Charhi • N. Mansouri • A. Harmouch • A. Kili • M. El khorassani • M. El Khattab • M. Maher • S. Sefiani	ERMS	Orbit, cheek, maxilla, nasopharynx	5.39 years	males	2011	desmin, smooth muscle actin and myogenin
Eleanor Chen • Robert Ricciotti • Neal Futran • Dolphine Oda	ARMS	Maxillary sinus, cheek, alveolarridge, palate	-	-	-	-
Ludimila Lemes Mour, Beatriz Della Terra Mouco Garrido, Nelson Leonel Del Hierro Polanco, Mattheus Augusto Siscotto Tobia, Viviane da Silva Siqueira, Cassia Maria Fischer Rubira, Paulo Sérgio da Silva Santos	SPINDLE CELL / SCLEROSING	Head and neck	-	-	-	-



MATERIAL AND METHODS

“Pediatric” AND “rhabdomyosarcoma” AND “head and neck” were the words used in MEDLINE database using advance search strategy targeting different article categories between 2023 to 2010. The result was 52 articles, out of which we selected 7 articles based in the inclusion criteria. Inclusion criteria was of clinical case reports, case series, case studies, clinical trials,

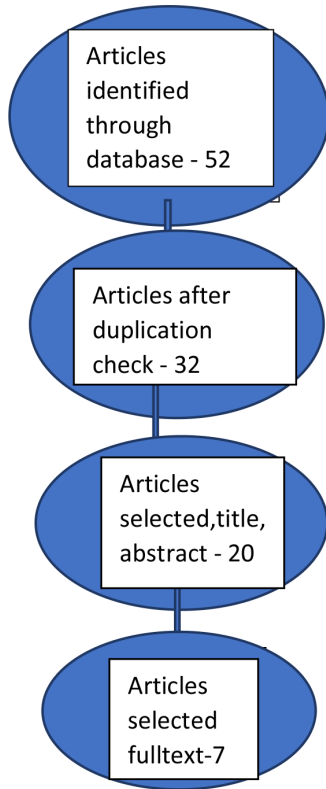


Fig.1: PRISMA flowchart

histopathologically confirmed cases, immunohistochemistry analysis, molecular analysis, primary tumour localization, age and scientific literature between 2010-2023. Exclusion criteria was of scientific literature devoid of original research, adults cases, RMS of different sites in paediatric population and cases without histopathological or immunohistochemical confirmation. This systematic review was conducted to determine RMS in pediatric patients in relation to head and neck region following the guidelines. The following data were collected: first author, year, country of study, type of study, patient sex, patient age, tumor location, tumor classification, tumor stage, histopathological analysis, immunohistochemical analysis, treatment, followup, mean survival, and outcome. The quality of studies was assessed using the STROBE (Strengthening the Reporting of Observational Studies) checklist.

RESULTS

We analyzed a total of 156 RMS cases mentioned in the seven articles reviewed. This included only original research articles and excluded articles pertaining to case reports of rhabdomyosarcoma in the head and neck region in patients of pediatric age. Anatomical sites included neck of paraspinal region, temporal bone, sphenoid sinus, ethmoid sinus, cavernous sinus, orbital region, sinonasal region, extradural space, nasopharynx, oropharynx, maxilla, mandible, buccal mucosa, conjunctiva and tongue. Subtypes included alveolar, spindle cell and embryonal. Age and gender distribution were observed. Histopathological features such as hyperchromatic nuclei, eosinophilic cytoplasm with small round blue cells were seen in embryonal type. Fibrovascular septae was seen in alveolar type. Hyper chromatic nuclei, scanty cytoplasm, spindle cells, myxoid stroma were seen in spindle cell type. Mesenchymal cells, myogenesis stages, rhabdomyoblasts with low cellular differentiation is observed in embryonal RMS.

Antibody	Clone	Dilution	Manufacturer	Retrieval	RMS comp	NED comp	Line of differentiation confirmed
VIM	V9	RTU	DAKO/ Denmark	High pH	+	+	Mesenchymal origin
DESM	D33	RTU	DAKO	High pH	+	-	Myogenic origin
MYO	F5D	1:100	ImmunoLogic/ Netherland	High pH	+	-	Rhabdomyosarcoma component
SA	Alpha Sr-1	1:100	DAKO	Citrate	+	-	Rhabdomyosarcoma component
NF	2F11	1:100	DAKO	Citrate	-	+	Neuroectodermal component
NSE	BBS/NC/V1-414	RTU	DAKO	High pH	-	+	Neuroectodermal component
CD99	12E7	RTU	DAKO	High pH	-	+	Neuroectodermal component

Comp: Component; DESM: Desmin; MYO: Myogenin; NED: Neuroectodermal; NF: Neurofilament; NSE: Neuron specific enolase; SA: Sarcomeric actin; RMS: Rhabdomyosarcoma; RTU: Ready to use; VIM: Vimentin.

Fig. 2: Brief overview on immunohistochemical markers in relation to rhabdomyosarcoma50.



Fusion genes, SRF-FOXO1 and SRF-NCOA1 were discovered. SRF-fused RMS might be a new subtype based on histology and genomics. Vimentin, desmin, myoglobin, and muscle specific actin were strongly positive in alveolar type. Cytoplasmic positivity for desmin and nuclei positivity for myogenin were observed in embryonal RMS, along with positivity for MyoD1. Desmin, myogenin and MyoD1 positivity was observed in spindle cell type. Well-differentiated RMS, with specific translocations of the SRF gene, expressed desmin and heterogeneous staining for myogenin and myoD1 in a diffuse manner leading to a finding that no immunomarker is specific in any subtype of RMS.

DISCUSSION

Annual incidence of 4 to 7 million children 15 years of age or younger and a male predominance are characteristics of RMS. Myogenic transcriptional regulators include Myogenin and MyoD1 which are expressed earlier in skeletal muscle differentiation followed by Desmin and myogenin³⁸⁻⁴⁰. Ablative surgery, moulage technique with afterloading brachytherapy and reconstructive surgery directed to the residual tumor after multiagent chemotherapy constitutes AMORE protocol. Patients' survival depends upon early diagnosis and management. Nasal obstruction, rhinorrhea, or recurrent otitis media forms the clinical scenario. Detection of sinonasal masses and delineation of the extent of the disease can be done by computed tomography and magnetic resonance imaging. Diagnosis can be confirmed by fiberoptic endoscopy and biopsy. Positive immunostains for desmin and myogenin and with negative staining for cytokeratin, epithelial membrane antigen, CD45, CD99, and S-100 are seen in RMS. Myogenin also stains ARMS. ARMS exhibits t(2;13)(q35;q14) translocation⁴¹⁻⁴⁵. Most common type of head and neck RMS is ERMS. Postoperative disfigurement, the high likelihood of leaving behind residual tumor, and the difficulty in excising any intracranial extension of the tumor are the postoperative complications. Origin from immature striated muscle dates to RMS which is one of the small round blue cell tumours of childhood mimicking neuroblastoma, Ewing's sarcoma, and lymphoma. Primitive spindle cells, often with a myxoid background are seen in ERMS associated with loss of heterozygosity at the 11p15 locus. Transcription factors that are physiologically expressed in the nuclei of striated muscular cells during embryonal and foetal development are MyoD1 and myogenin which are products of MYF3 and MYF4. Gross total tumour excision without distant disease, smaller tumour size (4–5 cm), younger age (4–10 years) and embryonal histology are favourable factors^{9,10,11,12,13}. Facial asymmetry, enamel defects, bony hypoplasia, trismus, velopharyngeal insufficiency, tooth and root agenesis, malformed or missing teeth, microdontia, maxillary and mandibular hypoplasia, disturbance in root development, poor tooth development, root stunting and xerostomia were the oral manifestations observed. Anatomical site, classification, histopathology, immunohistochemistry, clinicopathological correlation and molecular insight are described in this systematic review. The most common soft tissue sarcoma in paediatric population is rhabdomyosarcoma.

Meningeal or parameningeal are two types in head and neck RMS. The anatomical location in the head and neck region can be either parameningeal (nasopharynx, nasal cavities, paranasal sinuses, infratemporal and pterygopalatine fossae, and middle ear) or non-parameningeal. Prognosis and choice and course of treatment are decided by the anatomical location. In general, parameningeal RMS commonly presents with advanced disease and poor prognosis are observed in parameningeal type. Embryonal and alveolar are two main types of RMS. In younger children embryonal RMS is seen. In older children and adolescents, alveolar type is seen. Embryonal RMS affects the head and neck. Variable differentiated rhabdomyoblasts within loose, myxoid mesenchyme, with alternating areas of dense and loose cellularity are seen in embryonal RMS. ARMS is highly cellular and composed of primitive round cells with scant cytoplasm, hyperchromatic nuclei, fibrovascular septa, central loss of cellular cohesion and irregular alveolar spaces. Pale eosinophilic cytoplasm and blunted, ovoid fusiform, centrally located nuclei with small inconspicuous nucleoli are observed in spindle neoplastic cells. Histological classification includes embryonal rhabdomyosarcoma, with botryoid and anaplastic subtypes and alveolar rhabdomyosarcoma with solid variant. Myogenin stains >50% of tumor cell nuclei in alveolar RMS. 10% to 90% of tumor cells nuclei display variable myogenin stain in embryonal RMS. Strong nuclear MYOD1 staining is seen in spindle cell/sclerosing rhabdomyosarcoma^{14,15,16,17,18,19,20}. Alveolar RMS exhibit vimentin, desmin, myoglobin and muscle specific actin. Embryonal rhabdomyosarcoma display nuclei positivity for myogenin and cytoplasmic positivity for desmin. Tumor behavior, prognosis, or plan of treatment is decided by the histology and immunohistochemical marker^{24,25,26,37}. It should also be noted that it has been possible to identify an increasing variety of molecular anomalies in this type of sarcomas with the use of molecular techniques has enable us to identify various anomalies among the sarcomas. In our study, out of seven articles, only five articles had full details regarding rhabdomyosarcoma in relation to head and neck region of paediatric population⁴⁵⁻⁵⁰. Out of 52 articles, 32 were sent for duplication, resulting in prefinal 20 articles which had final output of seven articles.

CONCLUSION

Most common soft tissue sarcoma in children is Rhabdomyosarcoma. Epidemiological, histological and immunohistochemical aspects of head and neck RMS in children has been described. Survival for children with this malignancy has improved as a result of multiple factors, including better imaging and pathologic classification, use of multi-agent chemotherapy and use of appropriate radiotherapy especially in parameningeal primaries are the factors involved in quality of life and survival of paediatric population with RMS.

REFERENCES

1. Rodríguez-Vargas MP, Villanueva-Sánchez FG. Rhabdomyosarcoma of the head and neck in pediatric patients: a systematic review. *Med Oral Patol Oral Cir Bucal*. 2022 Nov 1;27 (6):e569-77.



2. C.R. de Andrade et al. Rhabdomyosarcoma of the Head and Neck: A Clinicopathological and Immunohistochemical Analysis of 29 Cases. *Braz Dent J* 21(1) 2010.
3. Atif Ali Ahmed, MD, and Maria Tsokos. Sinonasal Rhabdomyosarcoma in Children and Young Adults. *International Journal of Surgical Pathology* Volume 15 Number 2 April 2007 160-165.
4. Charhi et al. Epidemiological, histological and immunohistochemical analysis of head and neck rhabdomyosarcoma in children. *J. Afr. Cancer* (2011) 3:222-226 DOI 10.1007/s12558-011-0182-9.
5. Chen et al. Head and Neck Rhabdomyosarcoma: Clinical and Pathologic Characterization of Seven Cases. *Head and Neck Pathol* (2017) 11:321–326 DOI 10.1007/s12105-016-0771-0
6. Moura LL, Garrido BDTM, Del Hierro Polanco NL, Tobias MAS, da Silva Siqueira V, Rubira CMF, et al. Clinical-pathologic profile of head and neck rhabdomyosarcoma in children: a systematic review. *J Korean Assoc Oral Maxillofac Surg* 2023;49:61-67. <https://doi.org/10.5125/jkaoms.2023.49.2.61>
7. Radzikowska et al. Management of pediatric head and neck rhabdomyosarcoma: A case-series of 36 patients. *ONCOLOGY LETTERS* 12: 3555-3562, 2016
8. Perez EA, Kassira N, Cheung MC, Koniaris LG, Neville HL, Sola JE. Rhabdomyosarcoma in children: a SEER population based study. *J Surg Res.* 2011;170(2):e243–e51. doi: 10.1016/j.jss.2011.03.001.
9. Sultan I, Qaddoumi I, Yaser S, Rodriguez-Galindo C, Ferrari A. Comparing adult and pediatric rhabdomyosarcoma in the surveillance, epidemiology and end results program, 1973 to 2005: an analysis of 2,600 patients. *J Clin Oncol.* 2009;27(20):3391–3397. doi: 10.1200/JCO.2008.19.7483
10. Arul AS, Verma S, Arul AS, Verma R. Oral rhabdomyosarcoma-embryonal subtype in an adult: a rarity. *J Nat Sci Biol Med.* 2014;5(1):222–225. doi: 10.4103/0976-9668.127347.
11. Arya K, Vij H, Vij R, Rao NN. Rhabdomyosarcoma of mandible: a diagnostic predicament. *J Oral Maxillofac Pathol.* 2011;15(3):320–325. doi: 10.4103/0973-029X.86707.
12. Astekar M, Metgud R, Sharma P, Ramesh G. Oral alveolar rhabdomyosarcoma: a case report with immunohistochemical analysis. *Clin Pract.* 2012;2(1):e17. doi: 10.4081/cp.2012.e17.
13. Pappo AS. Rhabdomyosarcoma and other soft tissue sarcomas in children. *Curr Opin Oncol* 1996;8:311-316.
14. Arndt CA, Crist WM. Common musculoskeletal tumors of childhood and adolescence. *N Engl J Med* 1999;341:342-352.
15. Newton WA Jr, Gehan EA, Webber BL, Marsden HB, van Unnik AJ, Hamoudi AB. Classification of Rhabdomyosarcomas and related sarcomas. *Cancer* 1995;76:1073-1085.
16. Parham DM, Webber B, Holt H, Williams WK, Maurer H. Immunohistochemical study of childhood rhabdomyosarcomas and related neoplasms: results of an intergroup Rhabdomyosarcoma study project. *Cancer* 1991;67:3072-3080.
17. Lawrence W Jr, Anderson JR, Gehan EA, Maurer H. Pretreatment TNM staging of childhood rhabdomyosarcoma: a report of the intergroup Rhabdomyosarcoma study group. *Children's cancer study group. Pediatric Oncology Group. Cancer* 1997;80:1165-1170.
18. Hawkins DS, Spunt SL & Skapek SX Children's Oncology Group's 2013 blueprint for research: Soft tissue sarcomas. *Pediatric blood & cancer* 60, 1001–1008 (2013).
19. Crist WM, et al. Intergroup rhabdomyosarcoma study-IV: results for patients with nonmetastatic disease. *Journal of Clinical Oncology* 19, 3091–3102 (2001).
20. Crist W, et al. The Third Intergroup Rhabdomyosarcoma Study. *J Clin Oncol* 13, 610–630 (1995).
21. Raney RB, et al. The Intergroup Rhabdomyosarcoma Study Group (IRSG): Major Lessons From the IRS-I Through IRS-IV Studies as Background for the Current IRS-V Treatment Protocols. *Sarcoma.* 5, 9–15 (2001)
22. Arndt CA, et al. Vincristine, actinomycin, and cyclophosphamide compared with vincristine, actinomycin, and cyclophosphamide alternating with vincristine, topotecan, and cyclophosphamide for intermediate-risk rhabdomyosarcoma: children's oncology group study D9803. *J Clin Oncol* 27, 5182–5188 (2009).
23. Dasgupta, R.; Fuchs, J.; Rodeberg, D. Rhabdomyosarcoma. *Semin. Pediatr. Surg.* 2016, 25, 276–283.
24. Shern, J.F.; Yohe, M.E.; Khan, J. Pediatric Rhabdomyosarcoma. *Crit. Rev. Oncog.* 2015, 20, 227–243.
25. Ognjanovic, S.; Linabery, A.M.; Charbonneau, B.; Ross, J.A. Trends in childhood rhabdomyosarcoma incidence and survival in the United States, 1975–2005. *Cancer* 2009, 115, 4218–4226.
26. Parham, D.M.; Barr, F.G. Classification of rhabdomyosarcoma and its molecular basis. *Adv. Anat. Pathol.* 2013, 20, 387–397.
27. Radzikowska, J.; Kukwa, W.; Kukwa, A. Rhabdomyosarcoma of the head and neck in children. *Contemp. Oncol.* 2015, 19, 98–107.
28. Morotti RA, Nicol KK, Parham DM, Teot LA, Moore J, Hayes J, Meyer W, Qualman SJ; Children's Oncology Group. An immunohistochemical algorithm to facilitate diagnosis and subtyping of rhabdomyosarcoma: the Children's Oncology Group experience. *Am J Surg Pathol.* 2006 Aug;30(8):962-8.
29. Marco Wachtel et al. Subtype and Prognostic Classification of Rhabdomyosarcoma by Immunohistochemistry. *JCO* 24, 816-822(2006).
30. Sofija Glumac, Radoslav Davidovic, Branko Dozic, Sasa Hinic, Ivan Pavlovic, Dunja Drakulic, Ana Todorović, Maja Medojevic Pavlovic, Sanja Radojevic Skodric, Ivana Baralic, Jelena Sopta, Snezana Pejic, Immunohistochemical expression of cyclin-dependent kinase inhibitors p16 and p57 in rhabdomyosarcoma, *Pathology - Research and Practice*, Volume 225,2021,153558.
31. Radzikowska, J.; Czarnecka, A.M.; Klepacka, T.; Rychłowska-Pruszyńska, M.; Raciborska, A.; Dembowska-Bagińska, B.; Pronicki, M.; Kukwa, A.; Fendler, W.; Smyczyńska, U.; et al. Cancer Stem Cell Markers in Rhabdomyosarcoma in Children. *Diagnostics* 2022, 12, 1895
32. Elai Davicioni, Michael J. Anderson, Friedrich Graf Finckenstein, James C. Lynch, Stephen J. Qualman, Hiroyuki Shimada, Deborah E. Schofield, Jonathan D. Buckley, William H. Meyer, Poul H.B. Sorensen, Timothy J. Triche, Molecular Classification of Rhabdomyosarcoma—Genotypic and Phenotypic Determinants of Diagnosis: A Report from the Children's Oncology Group, *The American Journal of Pathology*, Volume 174, Issue 2,2009, Pages 550-564.
33. Rong Fan, David M. Parham, Larry L. Wang; An Integrative Morphologic and Molecular Approach for Diagnosis and Subclassification of Rhabdomyosarcoma. *Arch Pathol Lab Med* 1 August 2022; 146 (8): 953–959
34. Carter, R.L., McCarthy, K.P. (1992). Diagnosis of Rhabdomyosarcomas with Particular Reference to Immunohistochemical Markers. In: Fenoglio-Preiser, C.M., Wolff, M., Rilke, F. (eds) *Progress in Surgical Pathology*. Springer, Berlin, Heidelberg
35. Bertolini, G., Bergamaschi, L., Ferrari, A. et al. PD-L1 assessment in pediatric rhabdomyosarcoma: a pilot study. *BMC Cancer* 18, 652 (2018).
36. Virgone C, Lalli E, Bisogno G, Lazzari E, Roma J, et al. (2015) DAX-1 Expression in Pediatric Rhabdomyosarcomas: Another Immunohistochemical Marker Useful in the Diagnosis of Translocation Positive Alveolar Rhabdomyosarcoma. *PLOS ONE* 10(7):



37. Nathalie S.M. Lak, Timon L. Voormanns, Lily Zappeij-Kannegieter, Lieke M.J. van Zogchel, Marta Fiocco, Max M. van Noesel, Johannes H.M. Merks, C. Ellen van der Schoot, Godelieve A.M. Tytgat, Janine Stutterheim; Improving Risk Stratification for Pediatric Patients with Rhabdomyosarcoma by Molecular Detection of Disseminated Disease. *Clin Cancer Res* 15 October 2021; 27 (20): 5576–5585
38. Zambrano E, Pérez-Atayde AR, Ahrens W, Reyes-Múgica M. Pediatric Sclerosing Rhabdomyosarcoma. *International Journal of Surgical Pathology*. 2006;14(3):193-199.
39. Dziuba I, Kurzawa P, Dopierała M, Larque A, Januszkiewicz-Lewandowska D. Rhabdomyosarcoma in children – current pathologic and molecular classification. *Polish Journal of Pathology*. 2018;69(1):20-32.
40. Bostanci, A., Asik, M., & Turhan, M. (2015). Pediatric sinonasal rhabdomyosarcoma: A case report. *Experimental and Therapeutic Medicine*, 10, 2444-2446
41. Nör, Felipe DDS, MS, PhD*,†; Castro, Juan Pablo DDS, MS†; Wongpattaraworakul, Wattawan DDS†; Buatti, John M. MD†; Gordon, David MD, PhD§; Powers, Jennifer G. MD¶; Terry, William MD, MPH§; Hellstein, John DDS, MS†; Tanas, Munir MD®; Stone, Mary MD**. Cutaneous Metastasis of Alveolar Rhabdomyosarcoma in a Child. *The American Journal of Dermatopathology* 45(3):p e17-e21, March 2023
42. Huang, C., Jian, B., Su, Y. et al. Clinical features and prognosis of paediatric rhabdomyosarcoma with bone marrow metastasis: a single Centre experiences in China. *BMC Pediatr* 21, 463 (2021)
43. Furlong MA, Fanburg-Smith JC. Pleomorphic rhabdomyosarcoma in children: Four cases in the pediatric age group. *Annals of Diagnostic Pathology*. 2001;5(4):199-206
44. Erin R. Rudzinski, Lisa A. Teot, James R. Anderson, Julie Moore, Julia A. Bridge, Frederic G. Barr, Julie M. Gastier-Foster, Stephen X. Skapek, Douglas S. Hawkins, David M. Parham, Dense Pattern of Embryonal Rhabdomyosarcoma, a Lesion Easily Confused With Alveolar Rhabdomyosarcoma: A Report From the Soft Tissue Sarcoma Committee of the Children's Oncology Group, *American Journal of Clinical Pathology*, Volume 140, Issue 1, July 2013, Pages 82–90,
45. Leuschner I, Langhans I, Schmitz R, Harms D, Mattke A, Treuner J. p53 and mdm-2 Expression in Rhabdomyosarcoma of Childhood and Adolescence: Clinicopathologic Study by the Kiel Pediatric Tumor Registry and the German Cooperative Soft Tissue Sarcoma Study. *Pediatric and Developmental Pathology*. 2003;6(2):128-136.
46. Mondragón-Soto, M. G., Del Valle, L., González-Soto, J. A., and De Leo-Vargas, R. A. (2022). Metastatic primary brain rhabdomyosarcoma in a pediatric patient: illustrative case. *Journal of Neurosurgery: Case Lessons* 4, 4,
47. Agbanglanon, D. , M'barki, I. , Houessou, O. , Kietga, G. , Jaba, S. , Elouazzani, H. , Narcisse, S. , Elkacemi, H. , Cherradi, N. , Elmajjaoui, S. and Benjaafar, N. (2021) Pediatric Nasopharyngeal Rhabdomyosarcoma: About a Case and Review of Literature. *Journal of Cancer Therapy*, 12, 10-18.
48. Erin R. Rudzinski Histology and Fusion Status in Rhabdomyosarcoma. *Am Soc Clin Oncol Educ Book* 33, 425-428(2013).
49. Carpentieri, D., Nichols, K., Chou, P. et al. The Expression of WT1 in the Differentiation of Rhabdomyosarcoma from Other Pediatric Small Round Blue Cell Tumors. *Mod Pathol* 15, 1080–1086 (2002)
50. Satala, Catalin-Bogdan & Jung, Ioan & Bara, Tivadar & Simu, Patricia & Simu, Iunius & Vlad, Madalina & Szodorai, Rita & Gurzu, Simona. (2020). Primary rhabdomyosarcoma: An extremely rare and aggressive variant of male breast cancer. *World Journal of Clinical Cases*. 8. 4466-4474.

