ORIGINAL RESEARCH

# An Experimental Study of Oral Mucosal Wound Healing following Scalpel and Diode Laser Incisions in Guinea Pigs: Clinical and Histological Observations

Abdullah Saleh Almutairi[1], Dhafer S Alasmari[1], Minal Vaibhav Awinashe[2], Muzammil Moin Ahmed[3]

## Abstract

**Introduction:** The available data regarding scalpel and diode laser incisions wound healing is variable, scarce and needs more clarification especially in normal healthy tissues. Hence, this study was aimed to evaluate clinical and histologic parameters of wound healing with scalpel and diode laser on oral mucosa of Guinea pigs.

**Materials and Methods:** This is an experimental study conducted on four male Guinea pigs. Laser and scalpel incisions were made on the right buccal mucosa of each guinea pig approximately 5mm deep and 10 mm in length and both the incisions were placed 10 mm apart using No#11Bard Parker blades and diode laser (640 wavelength) under general anesthesia. Punch biopsies of both the incisions were obtained and compared for clinical changes such as ease of working, intra-operative bleeding, color and approximation of wound edges and histological changes such as epithelial proliferation, inflammation, angiogenesis, and fibrosis on day 1, 3 and 7.

**Results:** Clinically, scalpel wounds showed better healing than laser wounds although laser incisions provided bloodless surgical field. There was no significant difference in inflammation, angiogenesis and fibrosis between scalpel and diode laser incisions on both day 3 and 7 except for the epithelization which was comparatively early and better in scalpel wounds than the diode laser wounds.

**Conclusion:** Diode lasers provide bloodless surgical field with better visibility than scalpel without any difference in oral mucosal wound healing. Considering the clinical benefits, the diode lasers could be a superior alternative to conventional scalpel technique.

**Keywords:** Wound Healing, Lasers, Diode Lasers, Oral Mucosa, Guinea Pigs

Oral and Maxillofacial Pathology Journal (2023): ***https://www.ompj.org/archives.***

## Introduction

Enhanced healing of surgical wound is one of the prime medical and social concern which has led to the advancements in various diagnostic and clinical procedures and equipment, one of which is application of diode lasers in dentistry. The use of diode laser is increasing rapidly due to various advantages, the most important being providing bloodless surgical field and less postsurgical complications.[1,2] Newer advancements can facilitate eventual healing by providing prophylaxis against barriers to healing, augmentation of wound healing factors, assistance in temporizing and bridging time to definitive repair, and optimization of the ultimate results of wound reconstruction.[3]

Although wound healing mechanisms and specific cell functions in wound repair have been delineated in part, many underlying pathophysiological processes are still unknown.[4] All soft tissues generally follow the same pattern of wound healing but certain differences can be observed in relation to oral mucosal wounds. In comparison to skin wounds, the oral mucosal wounds heal rapidly with reduced scar formation.[5,6] Nonetheless, the oral cavity is a remarkable environment in

[1]Department of Periodontology and Oral Medicine, College of Dentistry, Qassim University, Buraidah, Al Qassim, Kingdom of Saudi Arabia, [2]Department of Maxillofacial Diagnostic Sciences, College of Dentistry, Qassim University, Buraidah, Al Qassim, Kingdom of Saudi Arabia, [3]Department of Dental Hygiene, College of Applied Health Sciences-Ar Rass, Qassim University, Al Qassim, Kingdom of Saudi Arabia.

**Corresponding Author:** Muzammil Moin Ahmed, Department of Dental Hygiene, College of Applied Health Sciences-Ar Rass, Qassim University, Al Qassim Region, Kingdom of Saudi Arabia. Email: mu.ahmed@qu.edu.sa

**How to cite this article:** Al Mutairi AS, Alasmari DS, Awinashe MV, Ahmed MM. An experimental study of oral mucosal wound healing following scalpel and diode laser incisions in guinea pigs: clinical and histological observations. Oral Maxillofacial Pathol J 2023;14(1): page no. 3-8

**Source of Support:** Nil

**Conflict of Interest:** None

*© 2023 Oral & Maxillofacial Pathology Journal, published by KSOMP. Open Access This article is distributed under the terms of the Creative Commons Attribution 4.0 International License (https://creativecommons.org/licenses/by-nc-sa/4.0/), which permits unrestricted use, distribution, and non-commercial reproduction in any medium, provided you give appropriate credit to the original author(s) and the source, provide a link to the Creative Commons license and indicate if changes were made. If you remix, transform, or build upon the material, you must distribute your contributions under the same license as the original. The Creative Commons Public Domain Dedication waiver (http://creativecommons.org/publicdomain/zero/1.0/) applies to the data made available in this article, unless otherwise stated.*

which oral mucosal wound healing occurs in warm oral fluid containing millions of microorganisms.[7] Oral mucosal healing encounters great challenge due to the existence of salivary, periodontal and other oral microbial load, alterations in mechanical oral forces, changes in oral temperature due to food intake and movements exerted by mastication.

The existing literature indicate the use of diode lasers could be an alternative to conventional surgical scalpel technique with added benefit of improved healing of tissues following procedures such as biopsy and excision of oral and periodontal lesions, teeth extractions, frenectomy, gingivectomy etc.[8-14] However, the available data is variable, scarce and needs more clarification especially in normal healthy tissues, not associated or modified by any inflammatory or disease process, which can potentially influence the healing of oral mucosal wounds. Considering the scarcity of literature regarding the healing of oral mucosal wounds in normal healthy tissues following diode laser and conventional scalpel surgical procedures, our investigation aimed to study the wound healing and also to find the best alternative for performing surgical incisions: a diode laser or a surgical scalpel.

## Materials and Methods

This experimental study was conducted to compare wound healing of incision made by diode laser and Scalpel on four male, healthy guinea pigs weighing 400, 400, 445, and 500 grams. The study protocol was as per national guidelines for animal research and approved by the ethical committee of Qassim University College of Dentistry with ethical clearance code ST/57/2019. No animal was sacrificed during the course of the study.

The incisions / surgical procedures were performed under short general anaesthesia (Figure 1). Ketamine (Ketalar inj) at the dose of 1mg per kg body weight was injected to all the four guinea pigs. Laser and scalpel incisions were made on the right buccal mucosa of each guinea pig approximately 5mm deep and 10 mm in length and both the incisions were placed 10 mm apart (Figure 2). The scalpel incisions were made using No#11 stainless steel Bard Parker blades whereas the laser incision was made using a diode laser (640 wavelength). The diode laser in continuous contact mode with protective eye glasses was used. The animals were fed with a special pellet diet and were under observation in animal home. No post-operative medications were given so as to avoid any influence on the normal healing process.

On the third day of surgery, punch biopsies were taken from two Guinea pigs using 8mm stainless steel punch. Identical biopsies were taken on the remaining two Guinea pigs on the seventh day of the incisions. The collected tissue samples were immediately fixed in 10% formalin. The biopsy samples were analysed histologically using Haematoxylin and Eosin (H&E) and Masson's Trichrome staining on 4um thin sections, for the presence of epithelial proliferation, inflammatory cells, vascularity and fibrosis. Each histological observation was recorded as absent, weak, moderate or good.

**Fig. 1:** The Guinea pigs under general anesthesia during the surgical procedure

**Fig. 2:** The laser incision on the top and the scalpel incision at the bottom
The laser incision on the top and the scalpel incision at the bottom

**Fig. 3:** Day 1 Day 3 Day 7

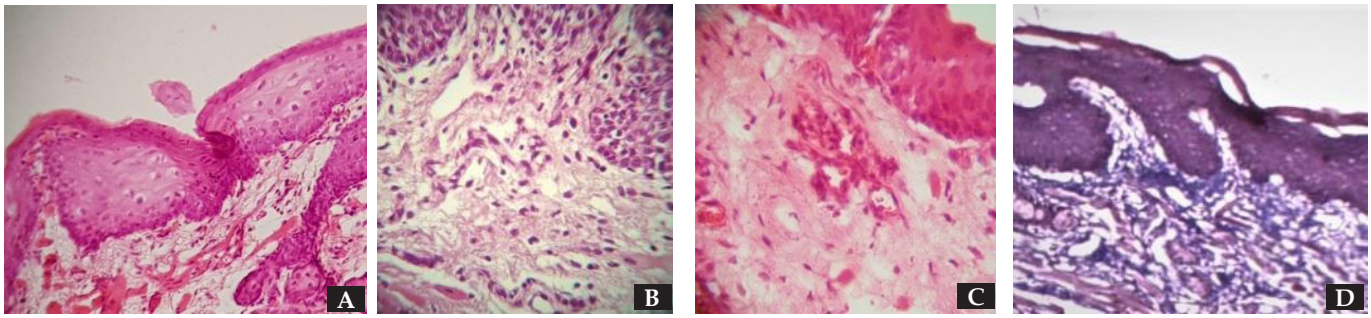


**Fig. 4:** Epithelial proliferation on day 3 **(A)**, inflammatory reaction **(B)**, angiogenesis **(C)** and Masson's trichrome stain shows fibrosis **(D)**.

Clinical and histological changes were observed and compared on day 1, 3 and 7 during healing of surgical wound (Figure 2). The Null hypothesis of this study was stated as "there is no difference in the oral mucosal wound healing and tissue response between the incisions made by scalpel or diode laser".

Statistical analysis was made using Chi-Square test to compare the histological findings seen with scalpel incisions and laser incisions regarding presence or absence of epithelial proliferation, inflammatory cell infiltration, angiogenesis and fibrosis at the incision sites.

## Results

**Clinical Findings:** During the surgical procedure, diode lasers provided bloodless field, whereas the scalpel incisions were accompanied by bleeding and blocked the surgical field. Clinical changes in healing wounds on day 1, day 3 and day 7 are shown in Figure 3. On day 3, the laser incision wound appeared greyish and flat, whereas scalpel incision appeared to be reddish and raised from surface. On day 7, edges of scalpel incision were well approximated and the incisions were barely visible whereas the laser incision was more identifiable and

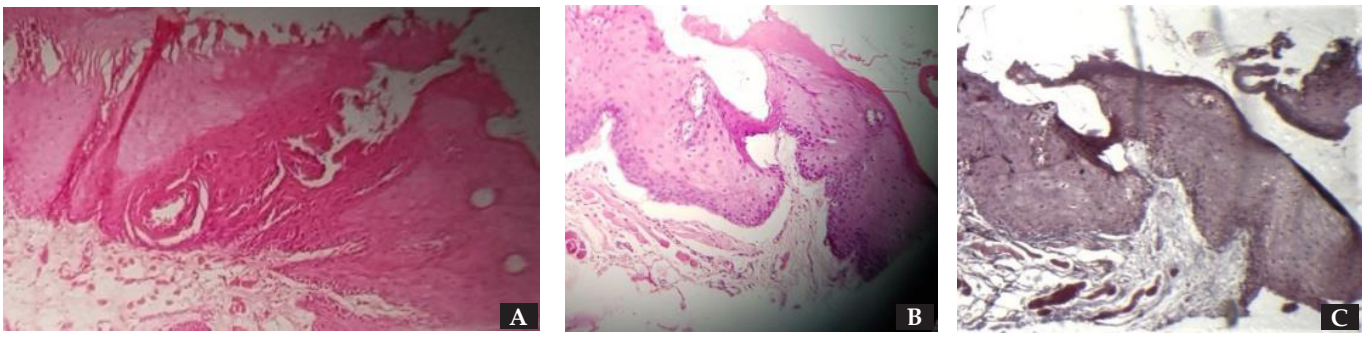


**Fig. 5:** laser incision - day 3 No epithelial proliferation **(A)**, no inflammatory reaction, less vascular **(B)** and Masson's trichrome stain shows no fibrosis **(C)**.

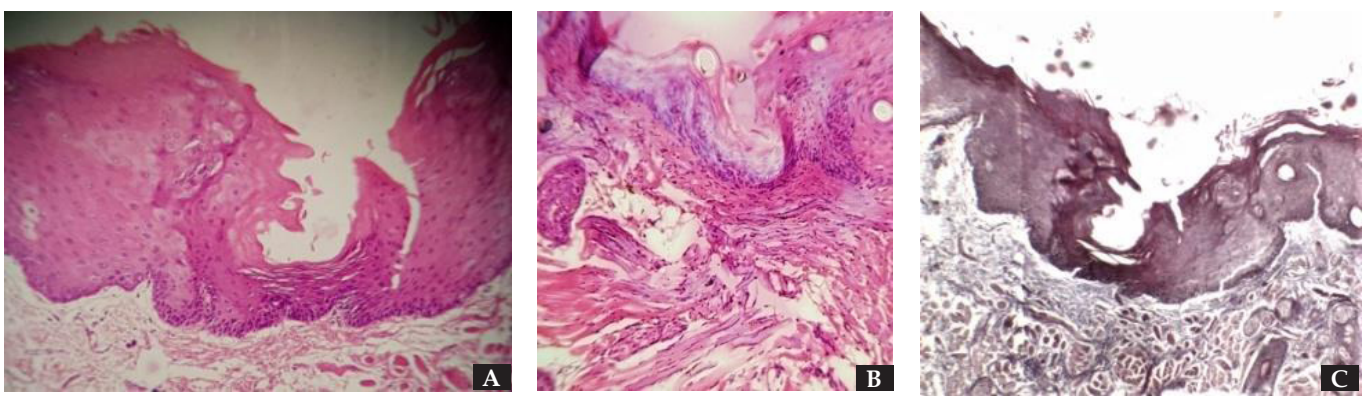


**Fig. 6:** Salpel incision day 7 complete epithelization **(A)**, mild inflammatory reaction and angiogenesis **(B)** and Masson's trichrome stain shows extensive fibrosis **(C)**.

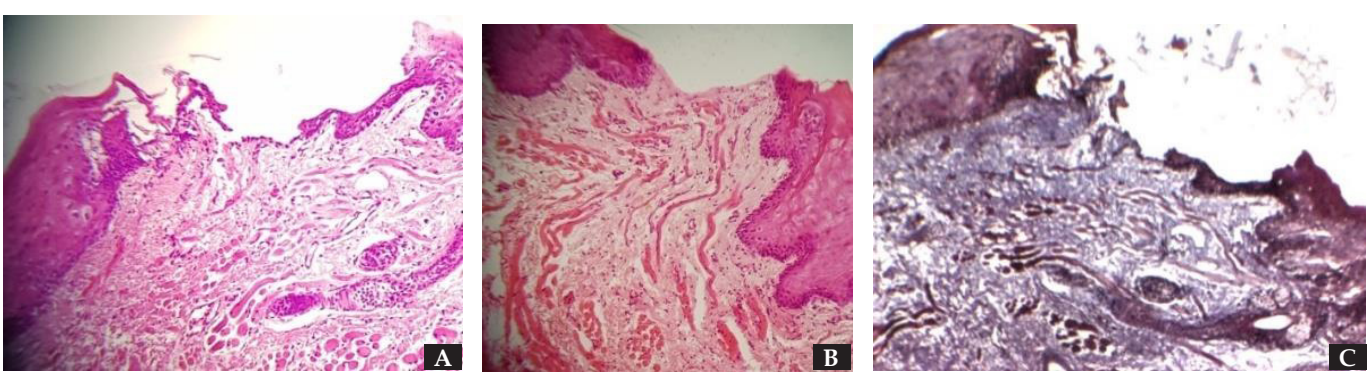


**Fig. 7:** Laser incision day 7 - mild epithelial proliferation on edges **(A)**, mild inflammatory reaction and angiogenesis **(B)** and Masson's trichrome stain **(C)**.

reddish.

**Histological findings:** On the day 3, all the 4 samples of scalpel incision showed epithelial proliferation with weak in 75% (n=3) and moderate in 25% (n=1). Epithelial proliferation was not evident (0.00%, n=0) in any of the section with diode laser incision. Inflammatory cell infiltration was seen in all sections of scalpel and laser incisions. In scalpel incision, the inflammation was weak in 25% of samples (n=1), moderate in 50% (n= 2) and good in 25% (n=1) whereas it was weak in 50% (n=2) samples and moderate in 50% (n=2) with diode laser incision. Angiogenesis was moderate in 25% of samples (n=1) and good in the 75% (n=3) with scalpel incision where as 75% (n=3) and 25% (n=1) were moderate and good respectively with diode incision. Weak fibrosis was observed in 75% (n=3) and moderate in 25% (n=1) in both scalpel and diode laser incisions. Figures 4 and 5 shows the histological changes on day 3 in scalpel and diode laser incisions respectively.

On 7th day, all the samples (100%, n=4) with scalpel incisions showed good epithelial proliferation while it was absent in 75% (n=3) and weak in 25% (n=1) with diode laser incisions. Inflammatory reaction was weak in both scalpel and diode laser incisions. Angiogenesis was moderate in 75% (n=3) and good in 25% (n=1) with scalpel incisions whereas weak in 75% (n=3) and moderate in 25% (n=1) with laser incisions. Scalpel incision showed weak fibrosis in 25% (n=1), moderate in 25% (n=1) and good amount of fibrosis in 50% (n=2) while all 4 samples (100%) with laser incision showed weak fibrosis. The histological changes observed on day 7 are shown in figure 6 and 7.

The statistical comparison of histological parameters on day 3 and 7 are presented in table 1 and 2 respectively. There was

**Table 1:** Comparison Between Scalpel and Laser on Day 3

| Day 3 | | Type | | | | | | p value |
|---|---|---|---|---|---|---|---|---|
| | | Scalpel | | Laser | | Total | | |
| | | No | % | No | % | No | % | |
| Epithelial Proliferation | Absent | 0 | 0.0% | 4 | 100.0% | 4 | 50.0% | 0.018* |
| | Weak | 3 | 75.0% | 0 | 0.0% | 3 | 37.5% | |
| | Moderate | 1 | 25.0% | 0 | 0.0% | 1 | 12.5% | |
| Inflammatory Cells | Weak | 1 | 25.0% | 2 | 50.0% | 3 | 37.5% | 0.513 |
| | Moderate | 2 | 50.0% | 2 | 50.0% | 4 | 50.0% | |
| | Good | 1 | 25.0% | 0 | 0.0% | 1 | 12.5% | |
| Angiogenesis | Moderate | 1 | 25.0% | 3 | 75.0% | 4 | 50.0% | 0.157 |
| | Good | 3 | 75.0% | 1 | 25.0% | 4 | 50.0% | |
| Fibrosis | Weak | 3 | 75.0% | 3 | 75.0% | 6 | 75.0% | 1 |
| | Moderate | 1 | 25.0% | 1 | 25.0% | 2 | 25.0% | |

*Significant at p<0.05

**Table 2:** Comparison Between Scalpel and Laser on Day 7

| Day 7 | | Type | | | | | | P value |
|---|---|---|---|---|---|---|---|---|
| | | Scalpel | | Laser | | Total | | |
| | | No | % | No | % | No | % | |
| Epithelial Proliferation | Absent | 0 | 0.0% | 3 | 75.0% | 3 | 37.5% | 0.018* |
| | Weak | 0 | 0.0% | 1 | 25.0% | 1 | 12.5% | |
| | Good | 4 | 100.0% | 0 | 0.0% | 4 | 50.0% | |
| Inflammatory Cells | Weak | 4 | 100.0% | 4 | 100.0% | 8 | 100.0% | |
| Angiogenesis | Weak | 0 | 0.0% | 3 | 75.0% | 3 | 37.5% | 0.082 |
| | Moderate | 3 | 75.0% | 1 | 25.0% | 4 | 50.0% | |
| | Good | 1 | 25.0% | 0 | 0.0% | 1 | 12.5% | |
| Fibrosis | Weak | 1 | 25.0% | 4 | 100.0% | 5 | 62.5% | 0.091 |
| | Moderate | 1 | 25.0% | 0 | 0.0% | 1 | 12.5% | |
| | Good | 2 | 50.0% | 0 | 0.0% | 2 | 25.0% | |

* Significant at p<0.05

no significant difference in inflammation, angiogenesis and fibrosis between scalpel and diode laser incisions on both day 3 and 7 except for the epithelization which was comparatively early and better in scalpel wounds than the diode laser wounds.

## Discussion

A dental surgeon faces a lot of changes during various dental procedures due to difficult access, vascular oral tissues with high potential for bleeding and abundant oral microflora. These challenges demand the need for equipment and therapeutic modalities that aid dental surgeons in easy functioning without hampering the wound healing. One such dental technological advancement is the use of diode lasers. Lasers are gaining popularity in dentistry for variety of procedures like surgical excision of benign lesions, frenectomy, operculectomy etc and also for vascular lesions and facial and gingival depigmentation.[1] Nonetheless, these technological advancements should not be at the cost of wound healing and patients' comfort. Therefore, researchers have compared healing between diode laser and scalpel made oral mucosal wounds.

In our study, the healing response to diode laser and scalpel incisions was studied on guinea pigs. Guinea pigs have many biological similarities to humans with the similarity of their immune systems to those of humans.[15] In our animal study, bloodless field and better surgical site visibility was observed with diode laser incisions. Similar findings were reported by Shalawae et al., who also found lesser aesthetic dose requirements and minimal post-operative complications with diode lasers.[16] Less post-operative complications and lower dose of anaesthesia associated with the diode laser incisions were also reported by Shahnaz et al. and Kaur et al. in their randomized clinical trials.[17,18] Nonetheless, lasers need a learning period for the operators and the cost of the equipment is high as compared to a simple surgical blade and the laser light is hazardous for eyes along with unpleasant odour during the procedure.[16] In the present study, the dose of anaesthesia could not be compared as both the incisions were done on same animal in single sitting.

In our study, the scalpel wound clinically appeared healed with well approximated wound edge than the laser wounds which were looking raw even on the 7th day which corresponded with the histological fast and better epithelisation in scalpel wound. This can be due to the epithelial down growth in the diode laser wounds as a result of laser-induced thermal necrosis of the wound margin and formation of a firm eschar that impedes epithelialization.[2]

Histological analysis in our study revealed more vascularity, inflammatory cells and budding capillaries in scalpel incision wound than diode laser wound which might have also contributed to the better epithelisation of scalpel incision wound. However, these changes weren't statistically significant except for the epithelisation. Also, histologically scalpel incisions showed more fibrosis adjacent to the incision than with the laser incisions but clinical wound contraction was not evident. This might be due to the fact that although fibroblast of oral mucosa produces more amount of collagen fibers as compared to the dermal fibroblast, they do not possess much contractile potency.[19]

Findings of our study were in similarity with the finding of a randomized controlled trial by Jonnalagadda et al. which reported no significant difference in the wound healing between the diode laser and conventional scalpel surgery in periodontitis patients.[20] A study by Kaur et al., showed better would healing with scalpel technique than diode lasers for second stage implant surgery.[18] However, our findings were in contradiction to the findings of a study by Arcangelo et al., which showed diode laser surgical procedure is able to guarantee a good healing.[21] Another study by Musaa et al., suggested that diode lasers can be effectively used in excision of chronic inflammatory gingival enlargements due to better clinical healing than the scalpel surgery.[12] Majority of these researches have studied the effect of diode lasers and scalpel in relation to wound healing in inflamed and/or diseased tissues unlike our study that investigated in healthy oral mucosal tissues of guinea pigs. Though inflammation is normal part of wound healing process, existing inflammation can prolong healing due to increased elevation of pro-inflammatory cytokines such as IL-1 and TNF-$\alpha$ induced by oral bacteria and their endotoxins.[22] Furthermore, components of oral biofilms and products produced by bacteria stimulate chronic inflammation which leads to persistently elevated levels of molecular components like proteases and reactive oxygen species that kill wound cells and damage proteins essential for healing.[23]

The limitation of our study is relative smaller sample size. Hence, further studies with larger sample size are recommended to support our study findings.

## Conclusion

Diode lasers provide bloodless surgical field with better visibility than scalpel without any difference in oral mucosal wound healing except for the faster epithelisation and early tissue approximation. Diode lasers could be a superior alternative to conventional scalpel technique considering clinical ease and benefits.

## References


1. Azma E, Safavi N. Diode laser application in soft tissue Oral Surgery. J Lasers Med Sci 2013; 4(4):206-211.
2. Fisher S E, Frame J W, Brown R M, Tranter R M. A comparative histological study of wound healing following Co2 laser and conventional surgical excision of canine buccal mucosa. Arch Oral Biol 1983; 28(4):287-291.
3. Shankar M, Ramesh B, Roopa Kumar D, Niranjan Babu M. Wound healing and its importance- A review. Der Pharmacologia Sinica. 2014; 1(1):24-30.
4. Heiko Sorg, Daniel J. Tilkorn, Stephan Hager, Jörg Hauser, Ursula Mirastschijski. Skin Wound Healing: An Update on the Current Knowledge and Concepts. Eur Surg Res 2017; 58:81–94.
5. Lin Chen, Zarema H Arbieva, Shujuan Guo, Phillip T Marucha, Thomas A Mustoe, Luisa A DiPietro. Positional differences in the wound transcriptome of skin and oral mucosa. BMC Genomics 2010; 11:471.
6. S. Enoch, R. Moseley, P. Stephens, D.W. Thomas. The oral mucosa: a model of wound healing with reduced scarring. Oral Surgery 2008; 1:11–21.
7. Constantinus Politis, Joseph Schoenaers, Reinhilde Jacobs, Jimoh O Agbaje. Wound Healing Problems in the Mouth. Front. Physiol. 2016; 7:507.
8. Purushottam Singh, Sonia Nath. Diode laser versus conventional technique for frenectomy - A randomised controlled clinical trial. Int J Appl Dent Sci 2019; 5(2):04-07.
9. Sandeep Kashyap, V V N Pavan Kumar, Piyush Prakash,

Naqoosh Haidry, Narahari Ranganath, D S J D'Souza. Comparison of Scalpel versus Soft Tissue Diode Laser for Biopsy of Oral Lesions. Int J Oral Care Res 2018; 6(2):50-55.

10. Berceste Guler, Sila Cagri Isler, Ahu Uraz, Suleyman Bozkaya, Fitnat Deniz Cetiner. The comparison of postoperative wound healing following different gingivectomy techniques: A randomized prospective clinical trial. Ann Med Res 2019;26(3):382-8.
11. Carmen Helena Jacques Lemes, Wellington Luiz de Oliveira da Rosa, Camila Leal Sonego, Bianca Jacques Lemes, Rafael Ratto Moraes, Adriana Fernandes da Silva. Does laser therapy improve the wound healing process after tooth extraction?A systematic review. Wound Rep Reg 2018; 27(1):102-113.
12. Farah E Musaa, Lutfi Ghulam Awazli, Faaiz Alhamdani, Saja G H Hussien. Diode laser 940nm versus scalpel surgery in the treatment of chronic inflammatory gingival enlargement. JODR 2019; 6(2):59-69.
13. Reza Amid, Mahdi Kadkhodazadeh, Mohammad Reza Talebi Ardakani, Somayeh Hemmatzadeh, Soheil Refoua, Parastoo Iranparvar. Using Diode Laser for Soft Tissue Incision of Oral Cavity. J Lasers Med Sci 2012; 3(1):36-43.
14. Luís Monteiro, Maria-Leonor Delgado, Fernanda Garcês, Mariana Machado, Fernando Ferreira, Marco Martins, Filomena Salazar, José-Júlio Pacheco. A histological evaluation of the surgical margins from human oral fibrous-epithelial lesions excised with CO2 laser, Diode laser, Er:YAG laser, Nd:YAG laser, electrosurgical scalpel and cold scalpel. Med Oral Patol Oral Cir Bucal. 2019;2 4 (2):e271-80.
15. K Vicari. The all-purpose guinea pig. Lab Anim 2014; 43(3):79.
16. Shalawe W S, Ibrahim Z A, Sulaiman A D. Clinical comparison between Diode laser and Scalpel incisions in oral soft tissue biopsy. Al- Rafidain Dent J 2012; 12(2):337-343.
17. Shahnaz A, Jamali R, Mohammadi F, Khorsand A, Moslemi N, Fekrazad R. A preliminary randomized clinical trial comparing diode laser and scalpel periosteal incision during implant surgery: impact on postoperative morbidity and implant survival. Lasers Med Sci 2018; 33:19 -25.
18. Kaur M, Sharma Y D, Singh P, Sharma S, Wahi A. Comparative evaluation of efficacy and soft tissue wound healing using diode laser (810nm) versus conventional scalpel technique for second-stage implant surgery. J Indian Soc Periodontol, 2018; 22(3):228-234.
19. Lee H G. and Eun H C. Difference between fibroblasts from oral mucosa and normal skin: implication to wound healing. J Dermatol Sci 1999; 21(3):176-182.
20. Jonnalagadda B D, Gottumukkala S N, Dwarakanath C D, Koneru S. Effect of diode laser-assisted flap surgery on postoperative healing and clinical parameters: A randomized controlled clinical trial. Contemp Clin Dent 2018; 9:205-12.
21. Arcangelo C.D., Di Maio F.D., Prosperi G.D., Conte E., Baldi M. and Caputi S. A preliminary study of healing of diode laser versus scalpel incisions in rat oral tissue: A comparison of clinical, histological and immunohistochemical results. O Surg, O Med, O Path, O Rad Endo 2007; 103(6):764-773.
22. S. Guo, L.A. DiPietro. Factors Affecting Wound Healing. Cri Rev Oral Bio Med. J Dent Res 89(3):219-229, 2010.
23. Fitridge R, Thompson M, editors. Mechanisms of Vascular Disease: A Reference Book for Vascular Specialists. Adelaide (AU): University of Adelaide Press; 2011.