

# Mucormycosis an Emerging Fungal Infection Associated with COVID-19- A Case Report

Arnab Bhattacharyya, Harish Kumar, Abikshyeet Panda, Niva Mahapatra

## ABSTRACT

**Introduction:** Mucormycosis is an exceptional but rising fungal infection correlated with the COVID-19 disease. COVID-19 positive patients exhibiting severe symptoms admitted in the ICU have an increased susceptibility to develop bacterial and fungal infection. We hereby report a case of oral mucormycosis that is seen in a patient in post COVID-19 infection.

**Case Presentation:** A 65-year-old woman presented to our institution, with the chief complaint of ulceration in her right palate region for the past 7 days along with pyrexia and generalised malaise. The patient reported to have recovered from COVID-19 infection recently. She presented with medical history of diabetes and hypertension for past 8 years. Post recovery from COVID-19 infection the patient developed an ulcer in the hard palate.

**Treatment:** Surgery was done under General anesthesia. Maxillectomy was done with aggressive debridement of necrotic tissue. Bilaterally periosteal flap was approximated and suture was placed.

**Conclusion:** The extensive use of steroids and broad-spectrum antibiotics in COVID-19 treatment may raise the risk of fungal infections. Medical practitioners should be aware of the possibility of invasive secondary fungal infections in patients with COVID-19 infection.

**Key words:** COVID-19, Mucormycosis, Fungal infections.

Oral and Maxillofacial Pathology Journal (2023): <https://www.ompj.org/archives>

## INTRODUCTION

Mucormycosis is an exceptional but rising fungal infection correlated with the COVID-19 disease. Post COVID-19 ailment, there is a surge in emergence of bacterial and fungal infections requiring a diligent awareness. Patients with COVID-19 severe illness treated in the intensive care unit (ICU) are ten times more prone to develop bacterial/fungal infections.<sup>1</sup>

Severe acute respiratory syndrome coronavirus 2 (SARS-CoV 2) is an illness caused by RNA virus Orthocoronavirinae, in the family Coronaviridae, order Nidovirales and family. Infection caused by a new type of severe acute respiratory syndrome in 2019 Corona virus 2 has been linked to a variety of illnesses, ranging from mild to life-threatening pneumonia. There are a variety of bacterial and fungal infections that can be related with pre existing morbidity viz-diabetes and lungs illness. Type 2 diabetes mellitus is most commonly seen in the Indian sub continent affecting 77 million individuals.<sup>2</sup> We hereby report a case of oral mucormycosis that is seen in a patient in post COVID-19 infection.

## CASE PRESENTATION

A 65-year-old woman presented to our college, Kalinga Institute of Dental Sciences with chief complain of ulceration in her right palate region past 7 days along with pyrexia and generalised malaise. The patient reported to have recovered from COVID-19 infection in the past two month. Patient was prescribed intravenous Meropenem (1 gm thrice daily),

Department of Oral Pathology, Kalinga Institute of Dental Sciences, Bhubaneswar, India.

**Corresponding author:** Arnab Bhattacharyya, Department of Oral Pathology, Kalinga Institute of Dental Sciences, Bhubaneswar, Odisha, Pin code - 751 024, India. Email: [arnab.bhattacharyya56@gmail.com](mailto:arnab.bhattacharyya56@gmail.com).

**How to cite this article:** Bhattacharyya A, Kumar H, Panda A, Mahapatra N. Mucormycosis an emerging fungal infection associated with COVID-19- a case report. Oral & Maxillofac Pathol J 2023;12(1): page no 116-119

**Source of Support:** Nil

**Conflict of Interest:** None

oral Oseltamivir (75 mg twice daily), with intravenous Methylprednisolone (40 mg twice daily) and Dexamethasone (4 mg twice daily), along with general supportive care. After admitted in hospital she was shifted to non invasive ventilation to maintain oxygen saturation. She presented with medical history of diabetes and hypertension and was on antihyperglycemic and antihypertensive medication respectively for past 8 years. Post COVID-19 infection the patient developed an ulcer in the hard palate measuring 3 X 1 cm, which gradually increased to the present size since 12 days and the colour of the surrounding area on the hard palate turned black with foul odour. On intraoral examination a whitish area was seen on the hard palate measuring 4 X 1

cm. extending from the incisive papillae anteriorly to two third of the hard palate posteriorly (Figure 1 and 2). On palpation the patient complain of severe sharp lancinating pain surrounding the whitish area that manifested as sequestrum. There was also a history of bleeding from the nose in the past one week. Cone beam computed tomography (CBCT) revealed complete opacification of right maxillary sinus with air entrapment with expansion of maxillary cortical plate with no involvement of periorbital region and zygoma (Figure 3).

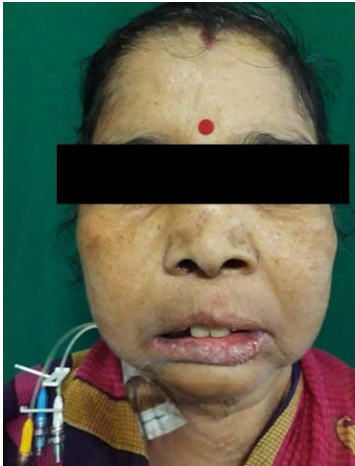Prior to biopsy blood investigations were performed and value for fasting blood sugar (FBS)-128 mg/dl [Normal range of FBS-70-110 mg/dL], Post prandial blood sugar (PPBS)-190 [Normal range of PPBS-<140mg/dL] mg/dl, Glycated hemoglobin (HbA1c)-7.0 [Normal range of HbA1c-5.6]. Histopathological examination revealed amorphous necrotic areas with admixture of mixed inflammatory cell infiltrate composed of neutrophils, lymphocytes and plasma cells (Figure 4). Lamellar bone with empty osteolytic lacunae suggestive of

dead bone was seen. In the Periodic acid-Schiff (PAS) staining numerous nonseptate branching fungal hyphae which branch at 90 degree angles were seen (Figure 5 and 6). The fungal elements are distributed near the blood vessels, these fungal branching, angioinvasion are suggestive of mucormycosis.

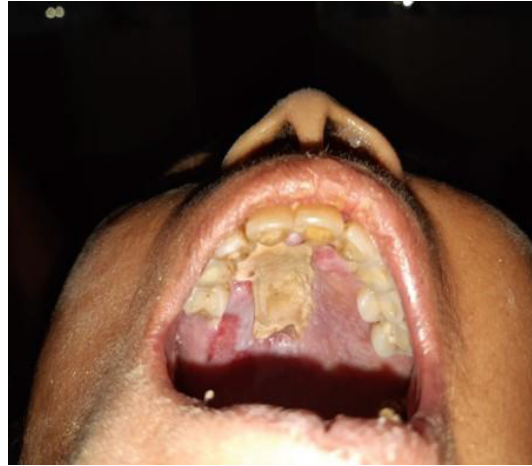Surgery was done under General anesthesia (GA) was administered. Extraction of 11-15, 21-28 was done. Mucoperiosteal flap was raised palatally with respect to 11-18, 21-28. Maxillectomy was done with aggressive debridement of necrotic tissue. Betadine soaked gauze pack placed and bilaterally periosteal flap was approximated and suture was placed with 3-0 vicryl.

## DISCUSSION

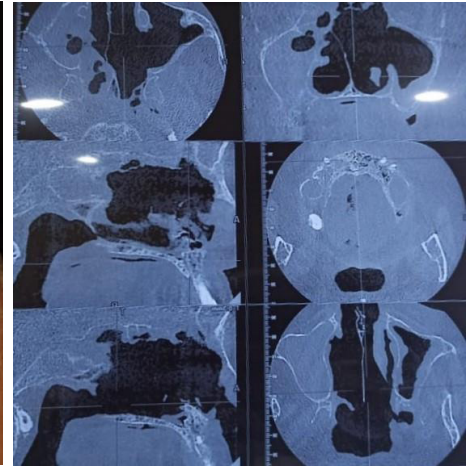
Mucormycosis is a multifaceted interconnection of factors, that includes- i) pre-existing diseases like diabetes mellitus, previous respiratory pathology, immunosuppressive therapy, ii) the risk of hospital-acquired infections, iii) systemic immune



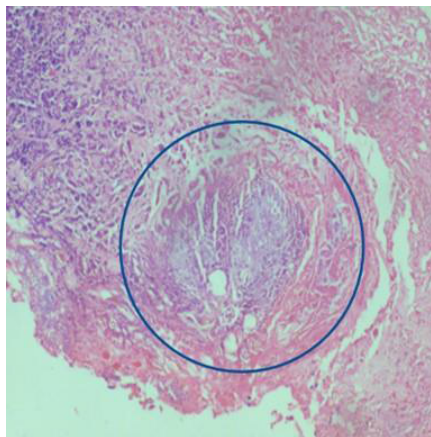
**Fig. 1:** Unilateral diffuse extraoral swelling on right side



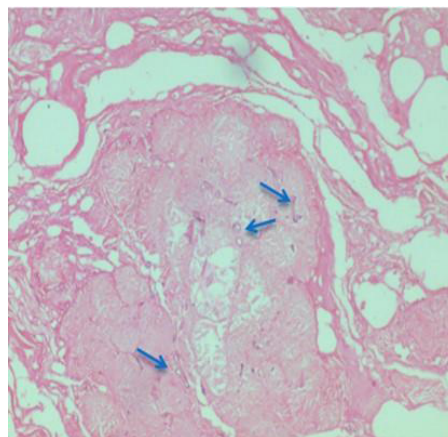
**Fig. 2:** Whitish area on the hard palate, extending from the incisive papillae anteriorly to two third of the hard palate posteriorly.



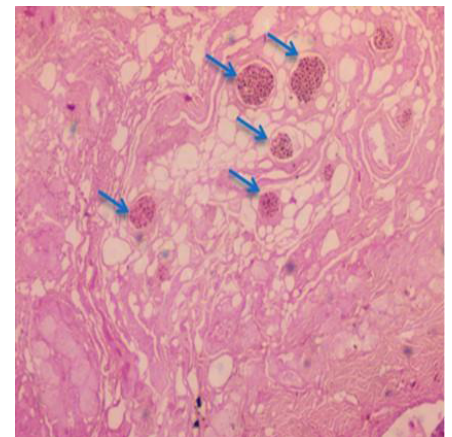
**Fig. 3:** Cone beam computed tomography (CBCT) revealed complete opacification of right maxillary sinus with air entrapment



**Fig. 4:** Encircled area in histopathological image shows an amorphous necrotic area with admixture of mixed inflammatory cell infiltrate (H&E stain, x10)



**Fig. 5:** Histopathological image shows numerous non septate branching hyphae of mucormycosis organism/mucorales (PAS stain, x10)



**Fig. 6:** Numerous spores of mucorales (PAS stain, x10)

alterations caused by COVID-19 infection itself.<sup>1</sup>

Authors like W Jeong et al<sup>3</sup>, De Pauw et al<sup>4</sup> have proposed that this can be fatal once the fungal components infiltrate blood arteries, causing mycotic thrombosis, ischemic infarction, and eventually necrosis of affected host tissues. Mucormycosis incidence has been estimated to range from 0.005 to 1.7 per million populations worldwide,<sup>3</sup> but the reported prevalence in India is 0.14 per 1000 person, the incidence of Mucormycosis is more prevalent in India than other industrialized countries.<sup>5</sup> The disease is expected to have a rapid clinical course, with a global mortality rate of 46%.<sup>6</sup> *Mucor*, *Rhizopus*, *Rhizomucor*, *Abdidia*, *Apophysomyces*, *Saksenaea*, and *Cunninghamella* are some of the Mucorales organisms that have been linked to the illness.<sup>7</sup> The fungus is frequently found in the nasal mucosa as commensal organisms. This fungus is noted specially in insulin dependent diabetics who have uncontrolled diabetes and ketoacidotic. Diabetes mellitus alters the body's normal immune response to infection in a variety of ways. Hyperglycemia promotes fungal growth by reducing chemotaxis and phagocytic effectiveness which allows otherwise harmless microbes to thrive in a highly acidic environment. Mucormycosis caused by *Rhizopus oryzae* is more common in diabetic ketoacidosis patients because these organisms produce the enzyme ketoreductase, which allows them to exploit the patient's ketone bodies. It has been proven that diabetic ketoacidosis causes a temporary disruption in transferrin's ability to bind iron, which disables a key host defensive mechanism and allows *Rhizopus oryzae* to thrive.<sup>8</sup> Fungal spores enter the body through inhalation and thrive in the paranasal sinuses. If not treated promptly, the disease may spread to nearby structures like orbit, cavernous sinus and cranium causing a variety of clinical symptoms.<sup>9</sup> Clinical symptoms of rhinocerebral mucormycosis is nasal obstruction, bloody nasal discharge, facial pain or headache, facial swelling or cellulites and visual disturbance with proptosis. If cranial nerve involvement occurs, then facial paralysis often presents.<sup>10</sup> Potential complications include cavernous sinus or sagittal sinus thrombosis, carotid occlusion, cerebral infarction, intracranial aneurysm, intracranial hemorrhage, and cerebral abscesses that can prove to be fatal to the affected patient. The infection can be characterized as i) sino-orbital<sup>11</sup> or rhinocerebral<sup>12</sup>, ii) pulmonary<sup>13</sup>, iii) cutaneous, iv) gastrointestinal<sup>14</sup>, or v) disseminated<sup>15</sup>. Rhinocerebro-orbital mucormycosis is the most prevalent kind (44-49%), followed by cutaneous (10-19%), pulmonary (10-11%), disseminated (6-11%), and gastrointestinal (2-11%) mucormycosis.<sup>16</sup> The mortality rate increases (53%) in patient with COVID 19 along subsequent fungal infection like mucormycosis.<sup>17</sup>

Diagnosis can be confirmed by biopsy and fungal culture. The appearances in microscope can vary but generally show wide, ribbon like filaments that generally do not have septa and branch at right angles, which may be seen to be invading blood vessels.<sup>18</sup> Once mucormycosis is detected, Amphotericin B at an initial dose of 1 mg is initially given by IV route slowly over 10-15 minutes, then given as a once daily dose according to body weight for next 14 days.<sup>19</sup>

Surgery can be very drastic and in some cases of disease involving the nasal and the brain, removal of infected brain tissue may be required. Removal of the palate, nasal cavity or

eye structures can be very disfiguring.<sup>20</sup>

In our case patient developed COVID-19 pneumonia was severe enough to necessitate invasive mechanical ventilation and after recovered from COVID-19 she developed mucormycosis and it is spread entirely in her right naso-orbital region despite of aggressive surgical removal of entire maxilla and surrounding structure patient was not survived.

## CONCLUSION

COVID-19 is linked to a high rate of bacterial and fungal secondary infections, most likely as a result of immune system instability. Furthermore, the extensive use of steroids and broad-spectrum antibiotics in COVID-19 treatment may raise the risk of fungal infections. Medical practitioners should be aware of the possibility of invasive secondary fungal infections in patients with COVID-19 infection, particularly in those with previous risk factors, and should be able to detect and treat these infections early, lowering mortality and morbidity.

## REFERENCES

1. Nambiar M, Varma SR, Jaber M, Sreelatha SV, Thomas B, Nair AS. Mycotic infections - mucormycosis and oral candidiasis associated with Covid-19: a significant and challenging association. *J Oral Microbiol.* 2021 Aug 26;13(1):1967699
2. International Diabetes Federation. (2020). Accessed October 31 2021: <http://idf.org/our-network/regions-members/south-east-asia/members/94-india.html>.
3. Jeong W, Keighley C, Wolfe R, et al. The epidemiology and clinical manifestations of mucormycosis: a systematic review and metaanalysis of case reports. *Clin Microbiol Infect.* 2019; 25(1):26-4.
4. De Pauw B, Walsh T, Donnelly J, et al. Revised definitions of invasive fungal disease from the European Organization for Research and Treatment of Cancer/Invasive Fungal Infections Cooperative Group and the National Institute of Allergy and Infectious Diseases Mycoses Study Group (EORTC/MSG) Consensus Group. *Clin Infect Dis.* 2008; 46(12):1813-21
5. Prakash H, Chakrabarti A. Global epidemiology of mucormycosis. *J Fungi (Basel).* 2019; 5(1).
6. Fox A, Janson B, Stiff H, et al. A multidisciplinary educational curriculum for the management of orbital compartment syndrome. *Am J Emerg Med.* 2020; 38(6):1278-80.
7. Amanda Werthman-Ehrenreich. Mucormycosis with orbital compartment syndrome in a patient with COVID-19. *American Journal of Emergency Medicine* 42 (2021) 264.e5–264.e8
8. Afroze SN, Korlepara R, Rao GV, Madala J. Mucormycosis in a diabetic patient: A case report with an insight into its pathophysiology. *Contemp Clin Dent* 2017;8:662-6
9. Shah K, Dave V, Bradoo R, Shinde C, Prathibha M. Orbital exenteration in rhino-orbito-cerebral mucormycosis: a prospective analytical study with scoring system. *Indian J Otolaryngol Head Neck Surg.* 2019;71(2):259-65.
10. Neville B, Damm D, Allen C, Chi A. Fungal and protozoal disease. Mucormycosis. *Oral and maxillofacial pathology.* 1st south asia ed. New Delhi: Elsevier India;2015.
11. Spellberg B, Edwards J Jr, Ibrahim A. Novel perspectives on mucormycosis: pathophysiology, presentation, and management. *Clin Microbiol Rev.* 2005; 18(3):556-69.
12. Sarkar S, Gokhale T, Choudhury SS, Deb AK. COVID-19 and orbital mucormycosis. *Indian J Ophthalmol.* 2021;69(4):1002-4.
13. Alekseyev K, Didenko L, Chaudhry B. Rhinocerebral Mucormycosis and COVID-19 pneumonia. *J Med Cases.* 2021; 12(3):85-9.
14. Johnson AK, Ghazarian Z, Cendrowski KD, Persichino JG. Pulmonary aspergillosis and mucormycosis in a patient with COVID-19. *Med Mycol Case Rep.* 2021;32: 64-7.



15. Monte Junior ESD, Santos MELD, Ribeiro IB, et al. Rare and fatal gastrointestinal mucormycosis (zygomycosis) in a COVID-19 patient: a case report. *Clin Endosc.* 2020; 53(6):746-9.
16. Moorthy A, Gaikwad R, Krishna S, et al. SARS-CoV-2, uncontrolled diabetes and corticosteroids-an unholy trinity in invasive fungal infections of the maxillofacial region? A retrospective, multi-centric analysis. *J Maxillofac Oral Surg.* 2021; 1-8.
17. Prakash H, Ghosh AK, Rudramurthy SM, et al. A prospective multicenter study on mucormycosis in India: epidemiology, diagnosis, and treatment. *Med Mycol.* 2019; 57(4):395-402.
18. Chamilos G, Lewis RE, Kontoyiannis DP. Delaying amphotericin B-based frontline therapy significantly increases mortality among patients with hematologic malignancy who have zygomycosis. *Clin Infect Dis.* 2008; 47(4):503-9.
19. Johnstone RB “ 25. Mycoses and Algal infections”. *Weedon’s Skin Pathology Essentials* 2nd edition Elsevier. 2017 p. 461.
20. Cornely OA, Alastruey-Izquierdo A, Arenz D, Chen SC, Dannaoui E, Hochhegger B, et al. “Global guideline for the diagnosis and management of mucormycosis: an initiative of the European Confederation of Medical Mycology in cooperation with the Mycoses Study Group Education and Research Consortium”. *The Lancet Infectious Diseases.* 2019;19 (12): 405–21.