

# Diagnostic utility of immunohistochemical markers in the diagnosis of Neoplasm of smooth muscle in head and neck region - A systematic review

Aswani E<sup>1</sup>, Gifrina Jayaraj<sup>2</sup>, Herald J. Sherlin<sup>3</sup>, K R Don<sup>4</sup>, Archana Santhanam<sup>5</sup>

## ABSTRACT

**Background:** The World Health Organization (WHO) system for defining and classifying soft tissue tumors is loyal applied to lesions that occur in the trunk and extremities, but it also provides a magnificent framework for characterizing nonepithelial extraskeletal tumors of the head and neck. Despite nonepithelial extraskeletal tumors are in the minority among head and neck lesions, they are by no means rare with high rate of recurrence, metastasis and high morbidity rate. Both clinical and radiographic features are not sufficient to diagnosis this disease because the transmission of carcinoma to sarcoma was unable to appreciate by this diagnostic criteria. Hence, we do IHC procedure to differentiate the disease.

**Aim and Objectives:** To systematically review the reliable varieties of IHC Markers and relevant markers for the diagnosis of neoplasm of smooth muscle origin.

**Material and Methods:** Articles were searched in PUBMED, MEDLINE and through google search. Hand search journal was also performed. With the use of a MESH database, 2 articles are included. From google search, 4 articles were identified based on the inclusion criteria one article excluded. Finally 5 articles were systematically reviewed and analysed.

**Results:** In all the studies, the strong and intense immunoreactivity for the alpha-SMA was observed in the cellular membrane of neoplastic cells in both leiomyoma and leiomyosarcoma. Even 80% of the studies show that focally positive of desmin for leiomyosarcoma and angiomyoma. Vimentin is strongly and intensely positive for smooth muscle tumours. The endothelial cells of vascular spaces are positive for CD34 for about 40% of the studies.

**Conclusion:** Alpha-SMA has been used to differentiate the smooth muscle tissue tumors from other spindle lesion and even from malignant conditions compared to vimentin, desmin and other neural makers. Alpha-SMA can be used as reliable and diagnostic markers for neoplasm of smooth muscle in head and neck region. Vimentin is a specific marker for leiomyosarcoma for identifying the significant high risk of recurrence, metastasis and even overall survival rate. CD34 is mainly used as a marker for the vascular leiomyoma and helps to differentiate with other malignant neoplasms.

**Key words:** Alpha-SMA, IHC markers, neoplasm, smooth muscle, Pubmed, Medline.

Oral and Maxillofacial Pathology Journal (2021): <http://www.ompj.org/archives>.

## INTRODUCTION:

Soft tissue tumors are a heterogeneous group of benign and malignant lesions that develop from various nonepithelial, extraskeletal elements, including adipose tissue, smooth and skeletal muscle, tendon, cartilage, fibrous tissue, blood vessels, and lymphatic structures<sup>1,2</sup>. Soft tissue tumors (STT) represent a complex group of lesions that may show a broad range of differentiation. According to the WHO classification system in 2002, soft tissue tumors are further subdivided according to their biologic behavior into benign tumors, intermediate tumors (those having malignant potential), and malignant tumors<sup>3</sup>. Based on the update, WHO classification in 2013 includes the following groups are adipocytic tumors, fibroblastic/myofibroblastic tumors, fibrohistiocytic tumors, smooth muscle tumors, pericytic (perivascular) tumors, skeletal muscle tumors, vascular tumors, gastrointestinal stromal tumors, nerve sheath tumors, chondro-osseous tumors, tumors of uncertain differentiation and undifferentiated/un-

<sup>1</sup> Junior Resident, <sup>2</sup> Reader, <sup>3</sup> HOD, <sup>4</sup> Reader, <sup>5</sup> Senior lecturer, Department of Oral pathology and Microbiology, Saveetha Dental College and Hospitals, Saveetha Institute of Medical and Technical Sciences, Saveetha University, Chennai- 600077.

**Corresponding Author:** Gifrina Jayaraj, Department of Oral pathology and Microbiology, Saveetha Dental College and Hospitals, Saveetha Institute of Medical and Technical Sciences, Saveetha University, Chennai- 600077. Email: gifrina@saveetha.com

**How to cite this article:** Aswani E, Jayaraj G, Sherlin HJ, Don KR, Santhanam A. Diagnostic utility of immunohistochemical markers in the diagnosis of Neoplasm of smooth muscle in head and neck region - A systematic review. Oral Maxillofac Pathol J 2021;12(1): page no. 26-30

**Source of Support:** Nil

**Conflict of Interest:** None

classified 1-1-1-1-1 sarcomas<sup>4</sup>. In 2017, the new classification has incorporated more detailed cytogenetic and molecular data in accordance with the rapidly increasing knowledge of genetics of tumors<sup>5</sup>. Soft tissue neoplasm of the head and neck are comparatively rare and account for less than 10% of all neoplasms.<sup>6</sup>

In fact, head and neck sarcomas represent an estimated 15% of sarcomas in adults and 35% of sarcomas in children<sup>7</sup>. Smooth muscle tumour is broadly classified as benign and malignant neoplasm<sup>4</sup>. Leiomyoma is a benign soft-tissue neoplasm arising from smooth muscle with incidence of leiomyoma in the oral cavity is 0.065%<sup>8,9,10</sup>. Leiomyosarcoma is the malignant smooth muscle tumor accounting for only 4% of the head and neck sarcomas<sup>11</sup>.

With a high rate of recurrence, metastasis and high morbidity rate. The clinical aspects of leiomyoma and leiomyosarcoma are similar to many other lesions of the oral cavity. Therefore, the differential diagnosis of leiomyoma in the oral cavity includes other benign conditions of the salivary glands. Both clinical and radiographic features are not sufficient to diagnose this disease because the transmission of carcinoma to sarcoma is difficult unable appreciate by this diagnostic criteria. The diagnosis is possible after histopathological and immunohistochemical analysis due to its nonspecific clinical features<sup>12</sup>.

Only a few immunohistochemical studies of oral and head and neck neoplasm of smooth muscle have been published. The purpose of the study is to evaluate the reliable IHC Markers for the diagnosis of neoplasm of smooth muscle in the head and neck region.

**MATERIAL AND METHODS:**

We performed a comprehensive literature search of PubMed, Google, Medline and Cochrane for relevant studies that examined the diagnostically reliable markers for neoplasm of smooth muscle in the head and neck region from 2010-2019. Several independent keywords in isolation and in combination were used, namely immunohistochemical markers, immunohistochemistry markers, diagnostic immunohistochemistry, applied immunohistochemistry, specific markers, diagnostic markers, leiomyoma, leiomyosarcoma and head and neck region was used. After screening titles and abstracts, the full text of 5 articles were retrieved for further review to

Table-1: Level of evidence of included studies  
\*Oxford center for Evidence- Based Medicine Levels of Evidence

S. NO	Author and year	Type of Study	Level of evidence
1	Nicolas et al in 2010	Cases series study	4
2.	Saavedra et al in 2018	Cases series study	4
3.	Ying liu et al in 2014	Cases series study	4
4.	Yoon et al in 2013	Cases series study	4
5.	Schutz et al in 2013	Cases series study	4

include in the study [Figure 1].

Articles that were not written in English, conference abstracts, studies not using human subjects or samples, reviews and articles pertaining to other head and neck cancers and studies with the influence of drug therapy were excluded. The inclusion criteria for the systematic review were articles on head and neck smooth muscle cancers, cross sectional studies, last 10 years and articles with the expression of immunohistochemical markers for smooth muscle neoplasm. Figure-1 shows the PRISMA flowchart

Due to the diversification of the reviewed studies, a meta analysis could not be performed. Yet a systematic review was done with the collected articles and the data obtained by doing so are tabulated and analyzed in Table 1 and Table 2.

**RESULT:**

In all the studies, the strong and intense immunoreactivity for the alpha-SMA was observed in the cellular membrane of neoplastic cells in both leiomyoma and leiomyosarcoma. Even 80% of the studies shows that focally positive of desmin for leiomyosarcoma and angiomyoma. According to Ying et al and Schutz et al, vimentin strong and intense positive for smooth muscle tumours. The endothelial cells of vascular spaces are positive for CD34 for about 40% of the studies. Proliferation marker like Ki-67, p16, p26 and even MSA, caldesmon and calponin was also 10% positivity for leiomyosarcoma. S-100 is also positive for few small neuron in the capsule mainly seen in angioleiomyoma. Major IHC markers for leiomyosarcoma are Vimentin and SMA. For leiomyosarcoma, mainly it was Alpha -SMA and Desmin.

**DISCUSSION:**

Smooth muscle tumors are comparatively very rare in the head and neck region. It was broadly classified as benign and malignant, namely leiomyoma and leiomyosarcoma. Leiomyoma are extremely rare in head and neck, and has very fidelity to be diagnosed because of its stringent histopathological criteria, like absence of nuclear atypia and of coagulative tumor necrosis. Also the tumours devoid of mitosis and atypia. An occasional, slightly pleomorphic cell in the midst of bland spindle cells, can be regarded as insignificant atypia. Leiomyosarcoma (LMS) of the head and neck are prob-

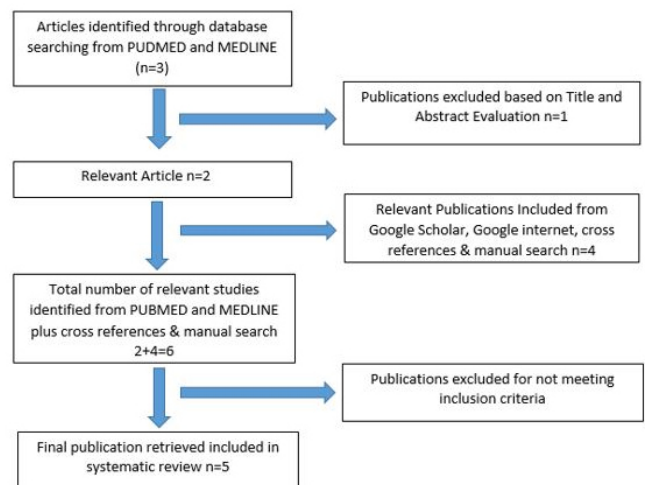


Fig 1 PRISMA flowchart

Study	Cases	Methods	Markers	Observation	Inferences	Limitation of the Study
Nicolas et al in 2010	41 (29 cases PLMS and 12 cases were DLMS)	IHC	α-SMA	Alpha-SMA is 100%(27/27)in leiomyosarcoma and 63% in pleomorphic sarcoma	LMS was strongly positive for myogenic markers and pleomorphic sarcoma has less focal and intense immunoreactivity	LMS has minimal for these variants extensive sampling of pleomorphic sarcoma will increase the areas of demonstrating the histology of LMS
			Desmin	Desmin is 86%(23/27)in leiomyosarcoma and 59%(16/27)in pleomorphic sarcoma		
			MSA	MSA in 90%(10/11) in leiomyosarcoma and 40%(4/10) in pleomorphic sarcoma		
			Caldesmon	57%(4/7) in leiomyosarcoma and 29%(2/7) in pleomorphic sarcoma		
			Calponin	90% (9/10) of for Leiomyosarcoma and 60%(6/10) cases for pleomorphic sarcoma		
			Vimentin	100% for 27/27 leiomyosarcoma and 28/28 in pleomorphic sarcoma.		
Saavedra et al in 2018	14 (angioliomyoma)	IHC	α-SMA	all cases positive	α-SMA is highly positive and good marker for ALM and help in the confirmation of diagnosis of the lesion	Not mentioned
			AE1/AE3	Negative		
			CD34	Positive for endothelial cells for 12 cases but 2 cases were negative		
			Desmin	all cases positive but variable pattern		
			CD68	Negative		
			S-100	Negative		
Ying liu et al in 2014	21(angioliomyoma)	IHC	α-SMA	Spindle - shaped tumor cells were positive	Positive expression strongly for α-SMA and Vimentin	Sample size is too small to draw any firm conclusion
			Desmin	Focally reactive		
			CD34	Positive for endothelial cells		
			Vimentin	positive		
			S-100	few small neurons are positive close to the capsule		
Yoon et al in 2013	12(Vascular leiomyoma)	IHC	α-SMA	ALL cases were positive	Vascular leiomyoma can be diagnosed by microscopy with H&E staining but IHC can contribute for differential diagnosis	case series would be small sample size for definite conclusions
			Desmin	Negative		
			CD31	Negative		
			CD34	Negative		
Schutz et al in 2013	7(leiomyosarcoma)	IHC	α-SMA	Positive for 5/5	Strongly positive for Vimentin and alpha SMA	Not mentioned
			Vimentin	Positive for 5/5		
			Desmin	Positive for 2/3		
			Ki-67	Positive for 2/7		
			p21	Positive for 2/7		
			p16	Positive for 4/7(57%)		

Table 2: Description of the included studies for the review.

PLMS- Pleomorphic Leiomyosarcoma; DLMS- Differentiated Leiomyosarcoma; LMS- Leiomyosarcoma; SMA-Smooth muscle actin; MSA-Muscle specific actin

ably rare and occur mainly in the arterial tunica media, ductus lingualis, circumvallate papillae, and pluripotent mesenchymal cells. The most frequent sites are the sinonasal tract (19%), the skin and soft tissue (16%), and WHO gives poor prognosis for primary LMS, "sinonasal tract leiomyosarcoma". LMS of the oral soft tissue has a better prognosis than LMS infiltrating the jaws, which has a significantly higher recurrence rate. It is very important to have proper follow up and detection of early initiation of recurrence of tumours. Is often challenging to diagnose only with histopathological diagnosis. Hence, immunohistochemistry helps in to differentiate the various patterns of smooth muscle tumors mainly in the head and neck region.

According to McCarthy et al in 2018<sup>13</sup>, leiomyoma is positive for SMA, Desmin and caldesmon but negative for the markers like S-100, SOX-10 and CD34 which is consistent with case series systematically reviewed like Ying et al<sup>14</sup>, Yoon et al<sup>15</sup>, Saavedra et al<sup>16</sup>, "Vascular leiomyoma have an additional CD34 positivity along with alpha-SMA and desmin," Most authors<sup>17,18,19,20</sup>, and <sup>21</sup> have accepted that VL originates from the smooth muscle in the walls of vascular channels because of that CD34 positive in immunohistochemistry around the vascular vessels.

All cases are strongly positive for vimentin in leiomyosarcoma<sup>22,23</sup>. This is because vimentin is a type III intermediate filament (IF) protein that is expressed in mesenchymal cells. Because of this, vimentin is particularly used as a marker of mesenchymal-derived cells or cells undergoing an epithelial-to-mesenchymal transition (EMT) during both normal development and metastatic progression. significantly worse

Most leiomyosarcomas are positive for SMA and MSA (HHF35), and less often for desmin. Desmin and MSA are generally markers of smooth and striated muscle respectively, and the tumors arising from these tissues, although these stains are not specific. However, some leiomyosarcomas are reported to be negative for desmin<sup>124,25</sup>.

Other smooth muscle markers are rarely known to be positive in leiomyosarcoma include calponin, SMMS-1, and caldesmon. The most specific of these antibodies is caldesmon, although not all (80%) leiomyosarcomas are reactive for this antibody<sup>26,27</sup>. It seems that the phenotypic shift of classic leiomyosarcoma to pleomorphic leiomyosarcoma is gradual with relatively complete smooth muscle expression in the better differentiated areas and eventual complete loss of smooth muscle phenotype in the undifferentiated foci<sup>25</sup>.

According to Schutz et al p16 is positive for 4 out of 7 cases. Tumor-suppressor protein p16 regulates the cell cycle in the G1 phase by inhibiting the cell proliferation through the inhibition of cyclin D-dependent kinase complex<sup>28</sup>. p16 lacking the in neoplastic cells seems to be associated with progressive tumor size and decreased overall survival<sup>29</sup>. p16 is expressed more frequently and strongly in LMSs compared with leiomyomas and is a useful antibody in detection of LMS from leiomyomas<sup>30</sup>. Similarly, like p16, LMS express p21, whereas lack of p21 seems to be associated with an increased risk of recurrence<sup>31</sup>.

From these studies, it is clearly indicated that Immunohistochemical markers like Alpha-SMA, vimentin and used as diagnostic reliable markers for Angioleiomyoma and leiomyosarcoma markers. p16 helps distinguish leiomyosarcomas from leiomyomas. These markers help to differentiate from other spindle cell tumors such as hemangioma, angiofibroma, fibroma, and angiolipoma

and even more complex disorders.

There is a lack of adequate number of currently published studies owing to the rarity of leiomyoma and leiomyosarcoma in the head and neck region. Further multicenter studies with cytogenetics might help us understand their behaviour in the head and neck region better.

## CONCLUSION:

From these studies, it clearly indicates that Alpha -SMA is a reliable marker for leiomyoma and leiomyosarcoma. CD34 is mainly used along with SMA and vimentin to identify vascular leiomyoma and helps to differentiate with other malignant neoplasms.

## ACKNOWLEDGEMENT:

The authors would like to acknowledge the help and support rendered by the Department of Oral Pathology & Microbiology of Saveetha Dental College and Hospitals and the management for their constant assistance with the research.

Source of funding: None

## REFERENCES:

1. De Schepper AM, Bloem JL. Soft tissue tumors: grading, staging, and tissue-specific diagnosis. *Top MagnReson Imaging*. 2007 Dec;18(6):431–44.
2. van Vliet M, Kliffen M, Krestin GP, van Dijke CF. Soft tissue sarcomas at a glance: clinical, histological, and MR imaging features of malignant extremity soft tissue tumors [Internet]. Vol. 19, *European Radiology*. 2009. p. 1499–511. Available from: <http://dx.doi.org/10.1007/s00330-008-1292-3>
3. Organization WH, Others. WHO Classification of tumours: pathology and genetics of tumours of soft tissue and bone. IARC Press: Lyon; 2002.
4. World Health Organization. WHO Classification of Tumours of Soft Tissue and Bone. IARC Press; 2013. 468 p.
5. Vilanova JC. WHO Classification of Soft Tissue Tumors [Internet]. *Imaging of Soft Tissue Tumors*. 2017. p. 187–96. Available from: [http://dx.doi.org/10.1007/978-3-319-46679-8\\_11](http://dx.doi.org/10.1007/978-3-319-46679-8_11)
6. Eeles RA, Fisher C, A'Hern RP, Robinson M, Rhys-Evans P, Henk JM, et al. Head and neck sarcomas: prognostic factors and implications for treatment. *Br J Cancer*. 1993 Jul;68(1):201–7.
7. Miller TT, Sofka CM, Zhang P, Khurana JS. Systematic Approach to Tumors and Tumor-Like Conditions of Soft Tissue [Internet]. *Diagnostic Imaging of Musculoskeletal Diseases*. 2009. p. 313–49. Available from: [http://dx.doi.org/10.1007/978-1-59745-355-4\\_8](http://dx.doi.org/10.1007/978-1-59745-355-4_8)
8. Kloefer HW, Krafchuk J, Derbes V, Burks J. Hereditary multiple leiomyoma of the skin. *Am J Hum Genet*. 1958;10(1):48.
9. Baden E, Doyle JL, Lederman DA. Leiomyoma of the oral cavity: A light microscopic and immunohistochemical study with review of the literature from 1884 to 1992. *Eur J Cancer B Oral Oncol*. 1994 Jan 1;30(1):1–7.
10. Weiss SW. *Histological Typing of Soft Tissue Tumours*. Springer Science & Business Media; 2012. 142 p.
11. Akcam T, Oysul K, Birkent H, Gerek M, Yetiser S. Leiomyosarcoma of the head and neck: report of two cases and review of the literature. *Auris Nasus Larynx*. 2005 Jun;32(2):209–12.
12. Osano H, Ioka Y, Okamoto R, Nakai Y, Hayashi H, Tsuchiya Y, et al. Angioleiomyoma of the cheek: a case report. *J Oral Sci*. 2015;57(1):63–6.
13. McCarthy AJ, Chetty R. Benign Smooth Muscle Tumors (Leiomyomas) of Deep Somatic Soft Tissue. *Sarcoma*. 2018 Sep 9;2018:2071394.
14. Liu Y, Li B, Li L, Liu Y, Wang C, Zha L. Angioleiomyomas in the head and neck: A retrospective clinical and immunohistochemical analysis. *Oncol Lett*. 2014 Jul;8(1):241–7.
15. Yoon TM, Yang HC, Choi Y-D, Lee DH, Lee JK, Lim SC. Vascular leiomyoma in the head and neck region: 11 years experience in one institution. *Clin Exp Otorhinolaryngol*. 2013 Sep;6(3):171–5.

16. Aitken-Saavedra J, da Silva K-D, Gomes A-P-N, Vasconcelos A-C-U, Etges A, Nóbrega T-G, et al. Clinicopathologic and immunohistochemical characterization of 14 cases of angioleiomyomas in oral cavity. *Med Oral Patol Oral Cir Bucal*. 2018 Sep 1;23(5):e564–8.
17. Stout AP. Solitary Cutaneous and Subcutaneous Leiomyoma [Internet]. Vol. 29, *The American Journal of Cancer*. 1937. p. 435–69. Available from: <http://dx.doi.org/10.1158/ajc.1937.435>
18. Montgomery H, Winkelmann RK. Smooth-muscle tumors of the skin. *AMA Arch Derm*. 1959 Jan;79(1):32–40; discussion 40–1.
19. DUHIG, T J. Vascular leiomyoma: A study of sixty-one cases. *Arch Pathol*. 1959;68:424–30.
20. Magner D, Hill DP. Encapsulated angiomyoma of the skin and subcutaneous tissues. *Am J Clin Pathol*. 1961;35:137–41.
21. Hachisuga T, Hashimoto H, Enjoji M. Angioleiomyoma. A clinicopathologic reappraisal of 562 cases. *Cancer*. 1984 Jul 1;54(1):126–30.
22. Nicolas MM, Tamboli P, Gomez JA, Czerniak BA. Pleomorphic and de-differentiated leiomyosarcoma: clinicopathologic and immunohistochemical study of 41 cases. *Hum Pathol*. 2010 May;41(5):663–71.
23. Schütz A, Smeets R, Driemel O, Hakim SG, Kosmehl H, Hanken H, et al. Primary and secondary leiomyosarcoma of the oral and perioral region--clinicopathological and immunohistochemical analysis of a rare entity with a review of the literature. *J Oral Maxillofac Surg*. 2013 Jun;71(6):1132–42.
24. Azumi N, Ben-Ezra J, Battifora H. Immunophenotypic diagnosis of leiomyosarcomas and rhabdomyosarcomas with monoclonal antibodies to muscle-specific actin and desmin in formalin-fixed tissue. *Mod Pathol*. 1988 Nov;1(6):469–74.
25. Perez-Montiel MD, Plaza JA, Dominguez-Malagon H, Suster S. Differential Expression of Smooth Muscle Myosin, Smooth Muscle Actin, H-Caldesmon, and Calponin in the Diagnosis of Myofibroblastic and Smooth Muscle Lesions of Skin and Soft Tissue [Internet]. Vol. 28, *The American Journal of Dermatopathology*. 2006. p. 105–11. Available from: <http://dx.doi.org/10.1097/01.dad.0000200009.02939.cc>
26. Sakamoto A, Oda Y, Yamamoto H, Oshiro Y, Miyajima K, Itakura E, et al. Calponin and h-caldesmon expression in atypical fibroxanthoma and superficial leiomyosarcoma. *Virchows Arch*. 2002 Apr;440(4):404–9.
27. Watanabe K, Kusakabe T, Hoshi N, Saito A, Suzuki T. h-Caldesmon in leiomyosarcoma and tumors with smooth muscle cell-like differentiation: its specific expression in the smooth muscle cell tumor. *Hum Pathol*. 1999 Apr;30(4):392–6.
28. Liggett WH, Sidransky D. Role of the p16 tumor suppressor gene in cancer [Internet]. Vol. 16, *Journal of Clinical Oncology*. 1998. p. 1197–206. Available from: <http://dx.doi.org/10.1200/jco.1998.16.3.1197>
29. Kawaguchi K-I, Oda Y, Saito T, Yamamoto H, Tamiya S, Takahira T, et al. Mechanisms of inactivation of the p16INK4a gene in leiomyosarcoma of soft tissue: decreased p16 expression correlates with promoter methylation and poor prognosis [Internet]. Vol. 201, *The Journal of Pathology*. 2003. p. 487–95. Available from: <http://dx.doi.org/10.1002/path.1419>
30. Bodner-Adler B, Bodner K, Czerwenka K, Kimberger O, Leodolter S, Mayerhofer K. Expression of p16 protein in patients with uterine smooth muscle tumors: an immunohistochemical analysis. *Gynecol Oncol*. 2005 Jan;96(1):62–6.
31. Dobashi Y, Noguchi T, Nasuno S. CDK-inhibitors-associated kinase activity: A possible determinant of malignant potential in smooth muscle tumors of the external soft tissue. *J Cancer [Internet]*. 2001; Available from: <https://onlinelibrary.wiley.com/doi/abs/10.1002/ijc.1479>.