

Mucous Membrane Pemphigoid

¹Sharlene Sara Babu, ²S Sunil, ³Akhilesh Pratap, ⁴Anuna Laila Mathew

ABSTRACT

Mucous membrane pemphigoid (MMP) is an uncommon autoimmune vesiculobullous lesion affecting mucosae of oral cavity, oropharynx, conjunctiva, genitalia and nasal cavity. Autoantibodies develop as a result of genetic and environmental factors, as in other autoimmune diseases. Complications include vision defects, hoarseness of voice, airway obstruction and dyspareunia. Microscopically, it is characterized by subepithelial blisters with the production of autoantibodies. Treatment varies from topical steroids to systemic steroid depending on the severity of presentation. Here, we report a case of MMP.

Keywords: Autoimmune, Bulla, Pemphigoid, Vesicle.

How to cite this article: Babu SS, Sunil S, Pratap A, Mathew AL. Mucous Membrane Pemphigoid. *Oral Maxillofac Pathol J* 2016; 7(1):702-705.

Source of support: Nil

Conflict of interest: None

INTRODUCTION

Mucous membrane pemphigoid (MMP) is an uncommon vesiculobullous lesion, presenting with a myriad of clinical manifestation. Females are more commonly affected than males (2:1), and occurring mainly in fifth or sixth decade of life, though children may also be affected.^{1,2} It affects all races and geographic areas. The incidence rate reported in European countries is about 1 per million per year. Wichmann (1794) first reported a female patient with ocular and oral involvement as well as skin lesions.¹ The diagnosis can be made by history, examination and biopsy with histopathology and direct immunofluorescent (DIF) examination.²

CASE REPORT

A 55-year-old partially edentulous female reported to outpatient department with the complaint of blisters on the upper and lower gums and palate. Patient noticed blisters since 2 weeks and blisters ruptured in 2 days time. She has no history of such skin diseases, so as is her family. On intraoral examination, thick-walled bullae were noticed in the maxillary right anterior alveolar ridge (Fig. 1) and mandibular anterior left gingivae (Fig. 2), hard and soft palate (Fig. 3). It appeared eroded and erythematous. Extraoral examination revealed an erythematous bulla on left side of face (Fig. 4), and on the trunk (Fig. 5). Ocular examination revealed adhesion of conjunctiva and lower eyelid of left eye (Fig. 6). Right

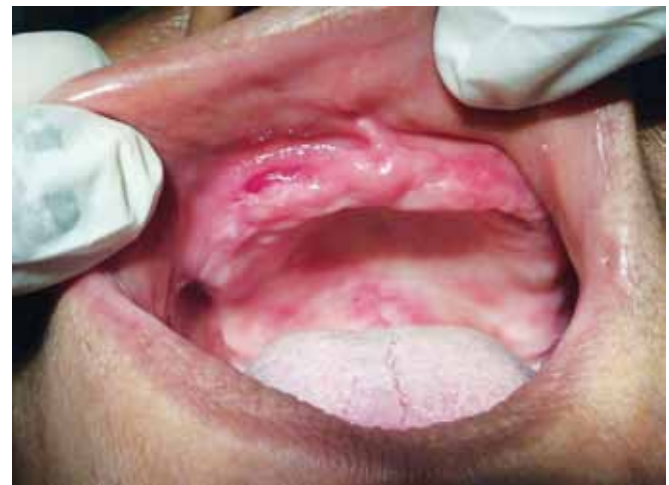

Fig. 1: Clinical photograph showing erythematous, thick-walled bulla on the right anterior alveolar mucosa

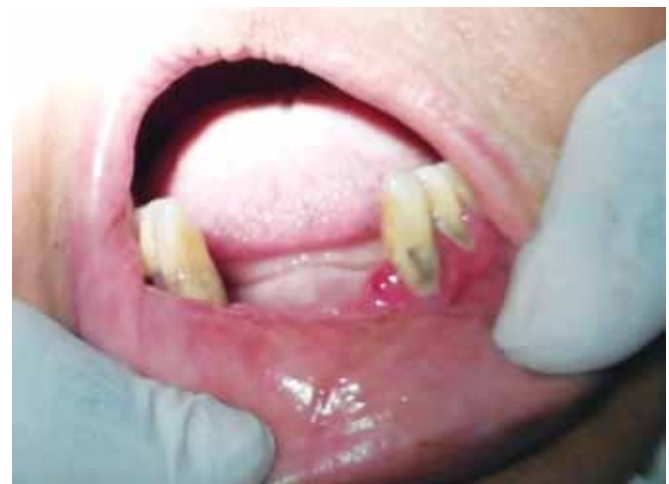

Fig. 2: Clinical photograph showing erythematous, thick-walled bulla on the left anterior gingiva

^{1,3,4}Reader, ²Professor and Head

^{1,2}Department of Oral and Maxillofacial Pathology, Pushpagiri College of Dental Sciences, Thiruvalla, Kerala, India

³Department of Oral and Maxillofacial Surgery, Pushpagiri College of Dental Sciences, Thiruvalla, Kerala, India

⁴Department of Oral Medicine and Radiology, Pushpagiri College of Dental Sciences, Thiruvalla, Kerala, India

Corresponding Author: Sharlene Sara Babu, Department of Oral and Maxillofacial Pathology, Pushpagiri College of Dental Sciences, Thiruvalla, Kerala, India, e-mail: dr_sharlene@rediffmail.com

eye was unaffected. No genital lesions were there. A provisional diagnosis of mucous membrane pemphigoid/pemphigus was made. After routine blood examination, Tzanck test and excisional biopsy of the gingival lesions was performed. Tzanck test was negative. Histopathological examination showed hyperplastic stratified squamous epithelium overlying a fibrous connective tissue. Subepithelial cleaving was noticed with the basal cells attached with the epithelium and dense chronic inflammatory cell infiltration was noticed in the connective tissue (Figs 7 to 9). Pemphigus vulgaris, desquamative gingivitis were considered in the differential diagnosis. Negative Tzanck test and presence of subepithelial blister formation ruled out pemphigus vulgaris. The classic clinical presentation of the lesion extraorally ruled out desquamative gingivitis. The patient was referred to dermatology and ophthalmology departments for expert consultation. After the expert opinion, the patient was treated with systemic corticosteroid. She was followed up for one month. The oral and skin lesions healed without

scarring. But, scarring occurred during the healing of eye lesion.

DISCUSSION

Mucous membrane pemphigoid is an autoimmune vesiculobullous lesion affecting mucosae of oral cavity (85%), oropharynx (19%), conjunctiva (64%), genitalia (17%) and nasal cavity (15%).^{1,3} Lesions often heal with scarring and hyper-pigmentation.^{3,4} Complications include vision defects, hoarseness of voice, airway obstruction and dyspare-unia.^{1,3,5} It is characterized by subepithelial blisters with the production of autoantibodies immunoglobulin G (IgG) (97%), C3 complement factor (78%) and, to a lesser degree, IgA (27%) and IgM (12%), targeted to certain components of the basal lamina of the epithelium. Immunoglobulin G accumulation has been documented between laminin 5 and type IV collagen at the dermal-epidermal junction.^{4,5} The variants of MMP include bullous pemphigoid and benign mucous membrane or cicatricial pemphigoid (CP).

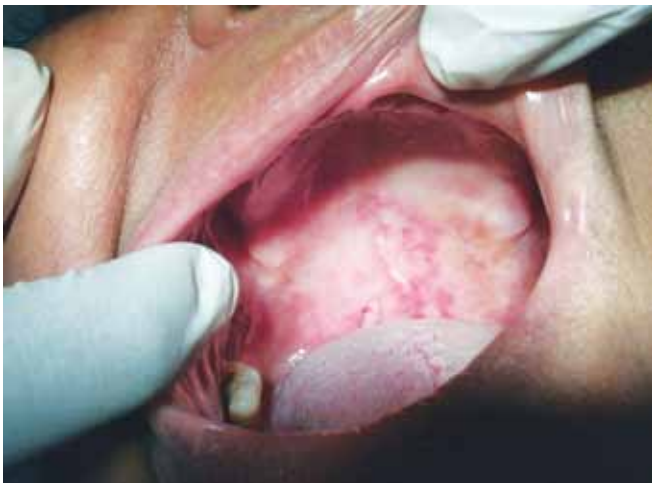

Fig. 3: Clinical photograph showing bulla and tissue tags on the hard and soft palates

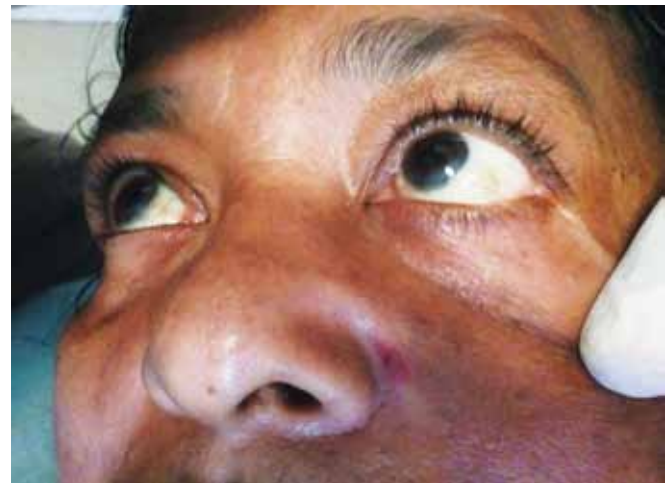

Fig. 4: Clinical photograph showing erythematous, thick-walled bulla on the left side of face above alae of nose

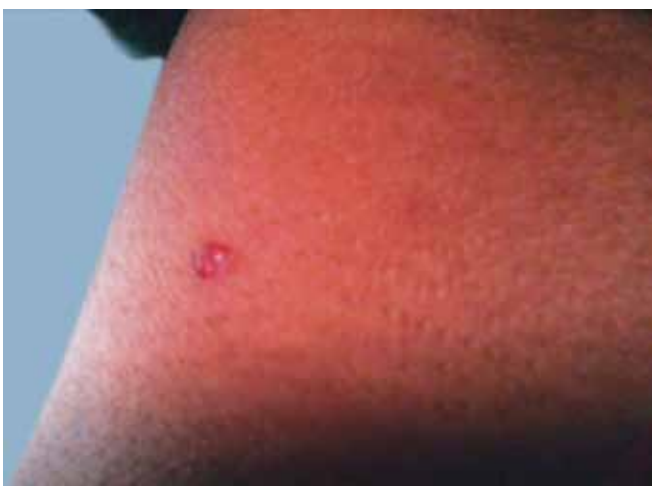

Fig. 5: Clinical photograph showing erythematous, thick-walled bulla on the right posterior trunk

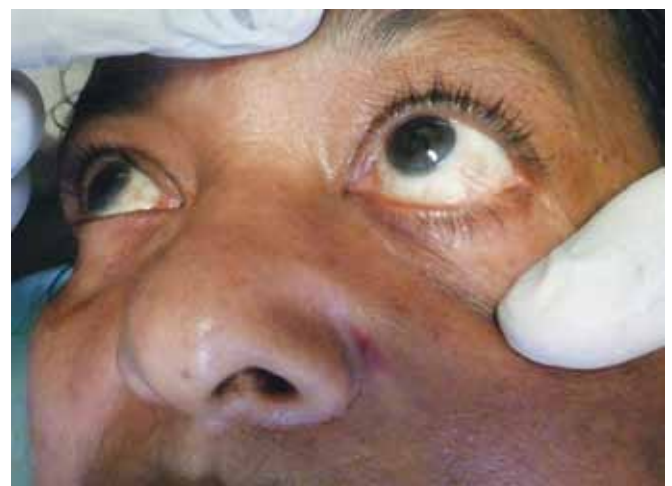

Fig. 6: Clinical photograph showing adhesion conjunctiva with lower eyelid

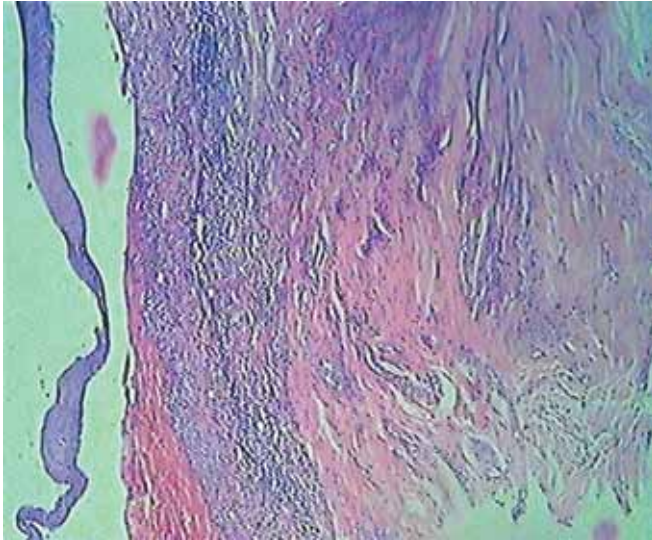


Fig. 7: Photomicrograph showing stratified squamous epithelium overlying connective tissue with sub-basal clefting (H&E, 10x)

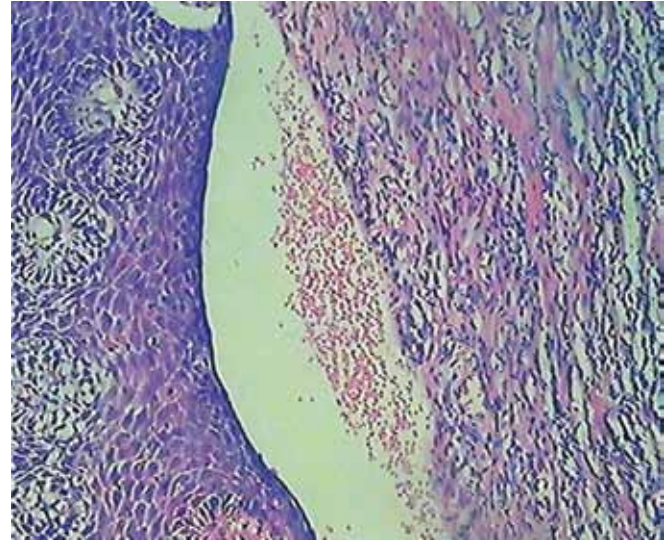


Fig. 8: Photomicrograph showing stratified squamous epithelium overlying fibrous inflamed connective tissue with subepithelial clefting (H&E, 40x)

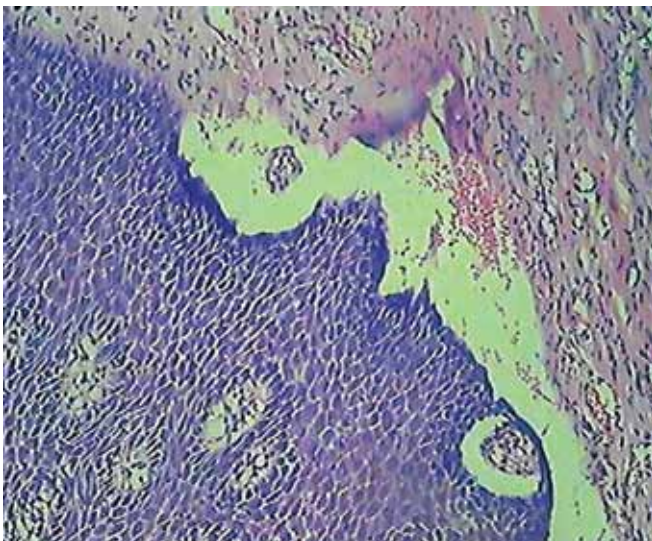


Fig. 9: Photomicrograph showing detached stratified squamous epithelium from connective tissue, with basal cells attached to epithelium (H&E, 40x)

The reported incidence in European countries is about 1 per million per year. The estimated incidence of ocular CP is between 1 in 8,000 and 1 in 46,000. Females are more commonly affected than males (2:1), and occurring mainly in fifth or sixth decade of life, though children may also be affected.^{2,3,6} It most commonly involves gingiva followed by soft and hard palate, presenting as thick walled bullae persisting for 1 to 2 days before rupturing, leaving raw, eroded erythematous or bleeding surface.^{4,7,8} Mucous membrane pemphigoid can be classified into six subgroups: oral pemphigoid, antiepiligrin pemphigoid, anti-BP Ag mucosal pemphigoid, ocular pemphigoid, a fifth group consists of patients with antibodies directed against more than one antigen, and anti-p200 pemphigoid by immunoassay techniques.⁵

Skin lesions, though uncommon, are located on the face, neck, scalp, trunk and extremities.⁵

Ocular lesions initially manifest as chronic conjunctivitis with burning sensation, irritation, photosensitivity and excessive lacrimation. Symblepharons involve conjunctiva and adhesions occur between palpebral and bulbar conjunctiva followed by ankyloblepharon and cicatricial bridles that can lead to blindness.^{3,7} The definitive diagnosis can only be established based on the histopathological data and immunofluorescence studies.^{1,7,8} Histopathologically, it is characterized by subepithelial blister without acantholysis.^{3,5,7} The underlying connective tissue shows a chronic inflammatory infiltrate composed of eosinophils, lymphocytes and neutrophils.^{4,8}

Direct immunofluorescent techniques show homogeneous IgG and C3 complement deposits along the junction between the connective tissue and epithelium. Indirect immunofluorescence (IIF) detect circulating antibodies in the serum of the patient.⁷

The treatment of benign MMP ranges from topical corticosteroids to systemic steroids depending on the location, severity and progression rate.^{1,4,7,8}

CONCLUSION

Mucous membrane pemphigoid resembles clinically and histopathologically with a variety of diseases. Since the means of investigations differentiating these diseases are specific, costly and not routinely used, this entity demands thorough clinical and histopathologic evaluation. An early detection and treatment is necessary to prevent complications.

REFERENCES

1. Ata-Ali F, Ata-Ali J. Pemphigus vulgaris and mucous membrane pemphigoid: update on etiopathogenesis, oral manifestations and management. *J Clin Exp Dent* 2011;3(3):e246-250.
2. Mostafa MI, Hassib NF, Nemat AH. Oral mucous membrane pemphigoid in a 6-year-old boy: diagnosis, treatment and 4 years follow-up. *Int J Paediatr Dent* 2010;20(1):76-79.
3. Schifter M, Yeoh SC, Coleman H, Georgiou A. Oral mucosal diseases: the inflammatory dermatoses. *Aust Dent J* 2010;55(Suppl 1):23-38.
4. Rajendran R, Sivapathasundharam B. *Shafer's Textbook of Oral Pathology*; Elsevier: 6th ed; 2009. p. 822.
5. Bagan J, Lo Muzio L, Scully C. Mucosal disease series—number III: mucous membrane pemphigoid. *Oral Dis* 2005; 11:197-218.
6. Talacko AA, Gordon AK, Aldred MJ. The patient with recurrent oral ulceration. *Aust Dent J* 2010;55(Suppl 1):14-22.
7. Scully C, Lo Muzio L. Oral mucosal diseases: mucous membrane pemphigoid. *Br J Oral Maxillofac Surg* 2008;46:358-366.
8. Neville WB, Damm DD, Allen CM, Bouquot JE. *Oral and Maxillofacial Pathology*. 3rd ed. Elsevier; 2009. p. 771-774.