

SCHWANNOMA PRESENTING AS PAPILOMA – A DIAGNOSTIC DILEMMA

Ashok Panchonia C. V. Kulkarni Rakesh Mehar Sourabh Mandwariya

Department of Oral & Maxillofacial Pathology, M.G.M. Medical College, Indore, Madhya Pradesh, India

Corresponding Author : Dr. Sourabh Mandwariya, B-20, Janta Colony, Sanjeet Road, Mandsaur, Madhya Pradesh, INDIA (PIN-458001)E-mail: dr_sourabh123@yahoo.com Telephone No. +91-9407101767

Abstract

Schwannomas are slow growing benign nerve sheath tumors. They are not commonly seen in the oral cavity and the tongue is the most common site of schwannomas found there.^[4] Here, we report a case of a tongue swelling presenting as a Papilloma clinically, which was histopathologically diagnosed as Schwannoma (Neurilemmoma) and discuss its clinical presentation, histological features and management.

Keywords : Schwannoma, Papilloma, Neurilemmoma, Nerve sheath tumors

Introduction

Neurilemmoma (schwannoma) is a benign, encapsulated perineural tumor of neuroectodermal derivation that originates from the Schwann cells of the neural sheath of motor and sensory peripheral nerves. In 1910, Verokay first described a group of neurogenic tumors; he referred them to as 'neurinomas'. In 1935, it was proposed that these tumors arose from nerve sheath elements and they were termed 'neurilemmomas'. Of the large variety of terms under which these tumors have been reported in the past, only three are still in current use: neurinoma, neurilemoma (neurilemmoma), and schwannoma.

Schwannomas may arise from cranial and spinal nerve roots or from peripheral nerves.^[1] Schwannomas have a predilection for sensory nerves. The vast majority of intracranial schwannomas arise from the eighth cranial nerve.^[7] Of the motor nerve, facial is most frequently involved.^[2] Spinal tumors arise predominantly from posterior roots. The lesion does occur with some frequency in patients with neurofibromatosis.

On occasions, the tumor can arise centrally within the bone and may produce bony

expansion. Intraosseous examples are most common in posterior mandible and usually appear as unilocular or multilocular radiolucencies on radiographs.^[5] Intramandibular tumours arise from mandibular nerve.

We report a case of Schwannoma of the tongue in a 25-year-old male presenting as Papilloma. This case has been reported for its different presentation.

Case Report

A 25-year old man presented with history of a slow growing swelling at the tip of the tongue since past 3 months. Swelling was not associated with pain. On local examination mouth opening was adequate. Oral hygiene was average. Tongue was not deviated and not atrophied. Single soft, tender, ulcerative growth of 3.00 cm x 3.00 cm is present over tip of the tongue. Lymph nodes draining the area were not palpable. Systemic examination was unremarkable. The hematological and biochemical parameters were within normal limits. Lesion was clinically diagnosed as Papilloma and an Incision biopsy was performed from the lesion. On histopathological examination incision biopsy was reported as an acute inflammatory lesion and an excision biopsy was advised.

An excision biopsy was performed and sent for histopathological examination.

Histopathological Examination

Gross Examination

Section received comprised of single gray brown soft tissue piece measuring 3.2 cm x 2.2 cm x 1.8 cm.

Microscopic Examination

Haematoxylin and Eosin stained sections studied show well encapsulated tissue consist of Schwann cells arranged in intersecting bundles forming Antoni A pattern and loose arrangement of cell in the form of Antoni B pattern. Cells with eosinophilic region (Verocay Bodies) are also seen. Features are that of Schwannoma (Fig1-4).

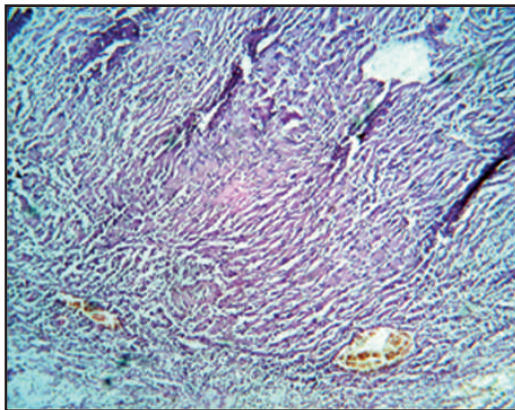


Fig : 1 (a) Low power view (H&E 4x)

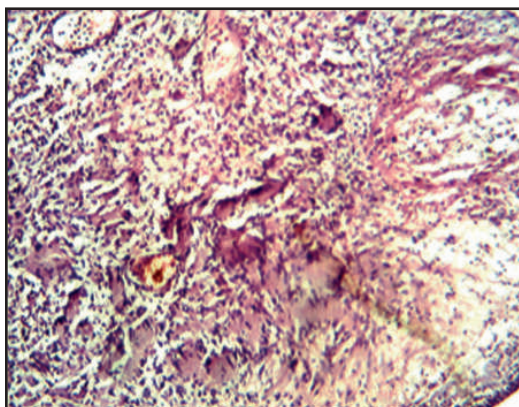


Fig : 2 Antoni A & Antoni B pattern (H&E 4x)

Discussion

Schwannomas are generally benign neoplasms arising from the Schwann cells of the peripheral nerve sheath. Because Schwann cells begin to invest cranial nerve processes within a few millimeters of the pial

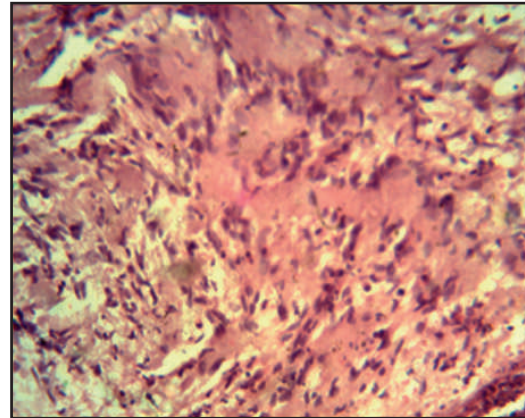


Fig : 3 Verocay Bodies (H&E 40x)

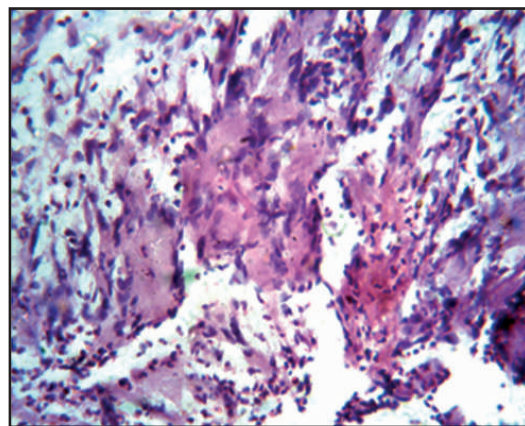


Fig : 4 High power view (H&E 40x)

surface of the brain and spinal cord, these neoplasms may arise within the spinal canal and cranial cavity, as well as in more peripheral locations. Although Schwannomas are often sporadic, their frequency is markedly increased in patients with neurofibromatosis, particularly in those with the central form of the disease (Neurofibromatosis type 2). Loss of the NF2 gene and its protein product merlin have been implicated in the development of sporadic schwannomas.^[8]

In the intracranial compartment, the vast majority of schwannomas arise in the eighth cranial nerve near the internal auditory meatus, where hearing loss and vertigo may call attention to the lesion at an early stage. Expansion of the meatus is often evident radiographically and, when present, helps to distinguish the schwannomas from other cerebellopontine angle tumors, including meningiomas and ependymomas. Less commonly, intracranial schwannomas may arise in the trigeminal, or other cranial nerves.

Within the spinal canal, most schwannomas arise in association with dorsal spinal nerve roots, where they present as circumscribed intradural masses, or as "dumbbell" shaped lesions protruding through adjacent intervertebral foramina. Rarely, they may present as a well-circumscribed mass within the spinal cord proper, sometimes in association with a syrinx. Foci of Schwann cell proliferation within the substance of the spinal cord, designated intramedullary "schwannosis," have been suggested as the likely precursor to such intramedullary tumors. Most schwannomas are solitary, although multiple lesions occur in some patients, especially in association with the central form of neurofibromatosis. Some schwannomas, particularly those dominated by compact Antoni-A architecture, may be difficult to differentiate from meningiomas. Demonstration of Epithelial Membrane Antigen (EMA) may be of great help in differentiating these two lesions, with EMA expression restricted to meningiomas. Electron microscopy may also be of value in problematic cases, with meningiomas exhibiting complex interdigitating cell processes and desmosomal attachments and lacking the well-developed pericellular basement membrane of schwannomas. An important variant to recognize is the so-called cellular schwannoma, which may be confused with well-differentiated forms of malignant peripheral nerve sheath tumor (MPNST). As in the case of other schwannomas, cellular variants may also arise in the Central Nervous System, particularly in association with the fifth or eighth cranial nerve. Cellular schwannomas, like their more conventional counterparts, are typically encapsulated lesions. Mitotic figures may be present, although mitotic rates are generally low. The presence of Antoni B tissue and hyalinized vessels and an absence of necrosis are additional features that help to distinguish cellular schwannomas from MPNSTs. Like more conventional schwannomas, the cellular variant exhibits robust S-100 reactivity and may also express Glial Fibrillary Acidic Protein (GFAP).

The treatment of a benign solitary neurilemmoma is enucleation. Excision of a segment of a major peripheral nerve is contraindicated.^[6] The lesion is excised marginally and the nerve fibers are spared. Recurrence is unlikely with complete resection. Patients usually have rapid and complete relief of pain, with excellent longterm results. Malignant change is extremely rare in isolated lesions.^[3]

References

1. Boustany A, McClellan WT. (2012) Schwannoma of the ulnar nerve: a case report and review of the literature. *W V Med J. Mar-Apr;108(2):36-8.*
2. Ferraz RC, Duarte JA, Fujita RR, Pignatari SS. (2012) Plexiform Schwannoma of the nasal tip: surgical approach. *Braz J Otorhinolaryngol. Jun;78(3):134.*
3. Gallesio C., Berrone S. (1992) Schwannoma located in the tongue. A clinical case report. *Istituto di Clinica Odontostomatologica, Universita degli Studi di Torino Dec;41(12):583-90.*
4. Husain S, Yunus MR, Ramli R, Athar PP (2011) Schwannoma of the tongue in a ten-year old child. *J Pak Med Assoc. May; 61(5):500-1.*
5. Lim A, Richards SW. (2012) Benign palmar schwannoma - a rare case in a handball player. *BMJ 14;2012.*
6. Varughese JK, Wentzel-Larsen T, Pedersen PH, Mabesparan R, Lund-Johansen M. (2012) Gamma Knife Treatment of Growing Vestibular Schwannoma in Norway: A Prospective Study.
7. Wad BK, Gourin CG, Francis HW (2012) Vestibular Schwannoma Surgical Volume and Short-term Outcomes in Maryland Vestibular Schwannoma Surgical Volume. *Arch Otolaryngol Head Neck Surg. Jun 1;138(6):577-83.*
8. Younes M, Simon E. (2012) Inferior alveolar nerve malignant schwannoma. *Rev Stomatol Chir Maxillofac. Jun 11. Int J Radiat Oncol Biol Phys. Jun 8.*

Source of Support - Nil

Conflict of Interest - None declared

How to cite this article:

Panchonia Ashok, Kulkarni C.V, Mehar Rakesh, Mandwariya Sourabh; Schwannoma Presenting As Papilloma – A Diagnostic Dilemma: *Oral Max Path J*, 4(2), July-Dec 2013: 376-378