



Macroscopy: A Guideline for Diagnosis

¹Usha Balan, ²S Vidyath, ³Samir Ahmed

ABSTRACT

Gross examination is most often neglected in surgical reporting of specimens. Gross features combined with history, clinical and radiographic examinations can always be a clue for the final diagnosis.

Keywords: Macroscopy, Gross, Diagnosis.

How to cite this article: Balan U, Vidyath S, Ahmed S. Macroscopy: A Guideline for Diagnosis. *Oral Maxillofac Pathol J* 2014;5(1):441-444.

Source of support: Nil

Conflict of interest: None

INTRODUCTION

Pathology is a wonderful science, which deals with the scientific study of structure and function of the body in disease. It involves both macroscopic and microscopic study of the tissue correlating it with the clinical and radiographic history, thus helping to arrive at an accurate diagnosis.¹ First opportunity for scientific study of disease came from thorough examination of body after death (autopsy). But this examination was confined to gross examination of organs only. This procedure was performed since about 300BC.²

The present day pathologist is concerned not only with the histopathologic examination of the specimen received but also the macroscopic detail of the specimen whether small or large. Though various advanced techniques have emerged in the diagnosis of disease, histopathological examination is one of the key techniques in diagnosis of diseases. Prior to making of tissue sections the macroscopic details have to be thoroughly recorded and studied as it may provide a clue for diagnosis.

Routine work associated with a surgical pathology specimen includes gross and microscopic examination. Chandler Smith stated in his essay, 'In praise of the gross examination, it is the gross aspect that shows the size, form and nature of the process so that it can be understood both in a structural sense and in a clinical context'.³

Smaller the specimen less significant gross examination appears to be. Many cases, an inadequate gross dissection

and sampling will invalidate the microscopic interpretation. The dissection, gross description and selection of sections for microscopic study is a crucial part of the pathologic examination, and one that often cannot be remedied if omitted or done poorly at the time of the initial work up. If microscopic description is inadequate, the slide can be reviewed and the problem corrected, if the dimensions of the specimen are not recorded, the key sections not taken, and the proper special studies not performed at the time of the initial gross examination, the chances of acquiring this information may be lost forever. Sometimes the reason the slide is so difficult to interpret is because of an inadequate sampling of the gross specimen.³

Parts of Surgical Pathology Report

- History
- Gross
- Microscopic description
- Diagnosis
- Note on comment.

Second part of the report known as 'gross' contains gross description of the specimen (s). This should be precise and thorough because once the gross specimen is discarded this description remains the only document by which the gross features of the case can be evaluated.

Specimens should be described in a logical sequential fashion, size, color, location of all lesions and weight of whole specimen should be recorded. It is important to be accurate, factual and noncommittal in the gross description, avoiding subjective interpretations as much as possible.³

General Principles of Gross Examination

Proper identification and orientation of the specimen are imperative for the adequate pathologic evaluation of a case. Careful search and examination of all material submitted should be done in order. Specimen especially if small should be handled on a clean cutting board using spotless clean instruments. Care should be taken not to contaminate with a fragment from another.

Place the specimen on the cutting board in an anatomic position and record following information.

- Type of specimen
- Structures included
- Dimensions
- Weight

¹Reader, ^{2,3}Senior Lecturer

¹⁻³Department of Oral Pathology, KMCT Dental College Calicut, Kerala, India

Corresponding Author: S Vidyath, Senior Lecturer, Department of Oral Pathology, KMCT Dental College, Mampetta, Calicut Kerala, India, Phone: 9947292862, e-mail: drvidyath@gmail.com

- Shape
- Color
- Identification of surgical margins.

The pathologist should keep in mind that in many surgical excisions the surgeon already knows the microscopic diagnosis of the lesion and he is now interested in informations such as extent of lesion, invasion of neighboring structures, presence of tumor at surgical margins, vascular invasion and lymph node metastasis.

Before dissection of specimen is begun, it is advisable to take gross photographs of external surface for documentation purposes. A properly made cross section will demonstrate important gross features of the lesion.³

- The recording of gross features should be in the order of which state the specimen was received followed by description of outer surface.
- Nature of the tissue whether hard, soft or cystic has to be recorded.
- Once dissection of the tissue is done properly description of the cut surface has to be made. If filled with some material like fluid, proper description of that material has to be done.
- Sections from representative area should be taken and sent for processing; remaining tissue should be preserved as such.
- No portion of the specimen be discarded before the case is signed out. The tissue should be preserved at least for a period of one month.³

SPECIMEN PHOTOGRAPHY

Documentation of the gross features of a surgical specimen is best achieved by taking one or several gross photographs of the lesion in the form of either color transparencies or digital images and incorporated into the corresponding case files.

Radiographic examination of surgical specimens sometimes provides important information. Specimens particularly suitable for this type of examination include bone lesions, calcified soft tissue masses, lymph node groups in which lymphangiogram has been performed.

IN CASES OF LYMPH NODE DISSECTION

The lymph nodes should be separated and labeled in groups according to the type of the specimen. All lymph nodes identified grossly are to be submitted for histopathologic examination.

SURGICAL MARGINS

One of the most important component of gross examination and sampling is the evaluation of surgical margins, under the assumption that a positive margin will likely lead to local recurrence if uncorrected. This is usually carried out by painting those margins with India ink or a similar pigment before sectioning; this can be done on either the fresh specimen or after fixation by gently wiping the margins with gauze and carefully covering the entire surgical surface with India ink using a cotton swab stick. Special care should be taken to mark the lateral epithelial margins of the specimen when present. If it is of importance to know the exact topography of the margins involved, this can be achieved by the surgeon identifying them individually and the pathologist submitting them for histology with a unique code identifier or by using dyes of different colors.

The 'gross' portion of the report is concluded by noting whether or not the entire specimen was submitted for microscopic examination and by including the name of the pathologist who performed gross examination.³

Examples of Few Cases Where Gross Features Helped us in Confirming the Surgical Report

Case 1: Appeared macroscopically as a soft tissue mass with an impacted tooth inside. Cut surface showed a variegated appearance with small areas of hemorrhage in a grayish white tissue. The soft tissue was not attached to the neck of the tooth. With the clinical history grossly we arrived at the diagnosis of Adenomatoid Odontogenic tumor which was later confirmed histologically (Fig. 1).

Case 2: Cystic cavity with lining attached to neck of the tooth and lining of the cyst slightly thicker unlike that of

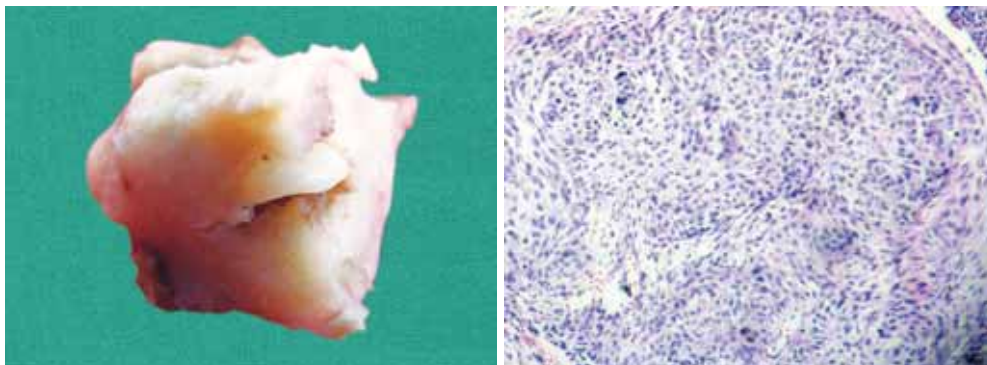


Fig. 1: Gross and microscopy of adenomatoid odontogenic tumor

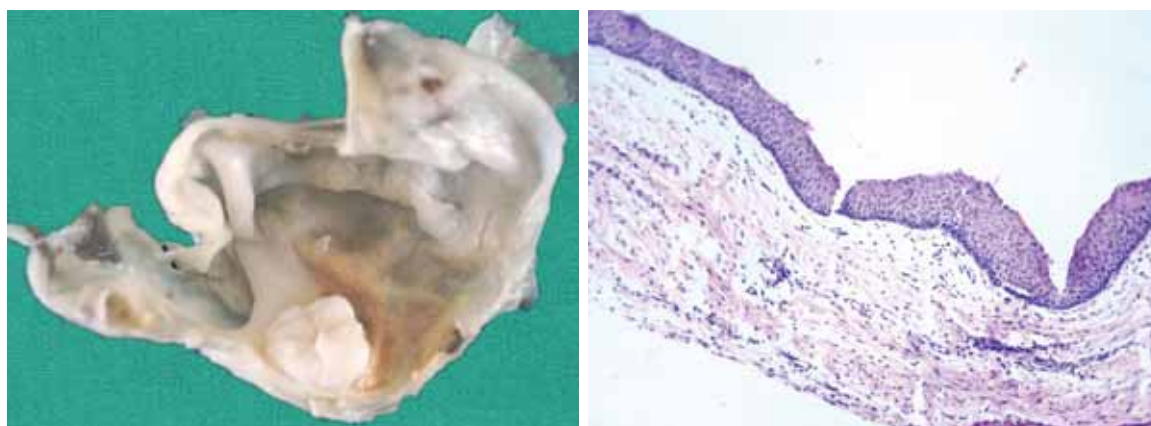


Fig. 2: Gross and microscopy of follicular keratocyst

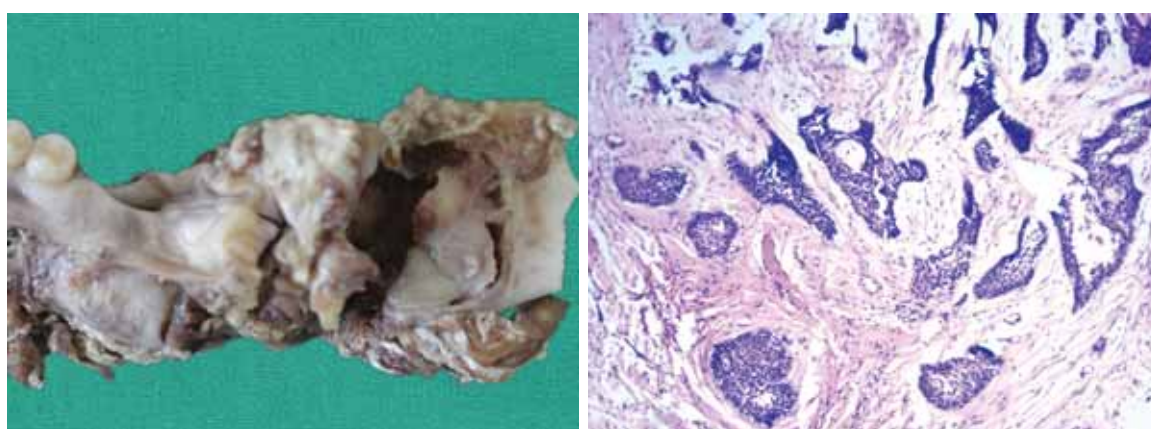


Fig. 3: Gross and microscopy of ameloblastoma

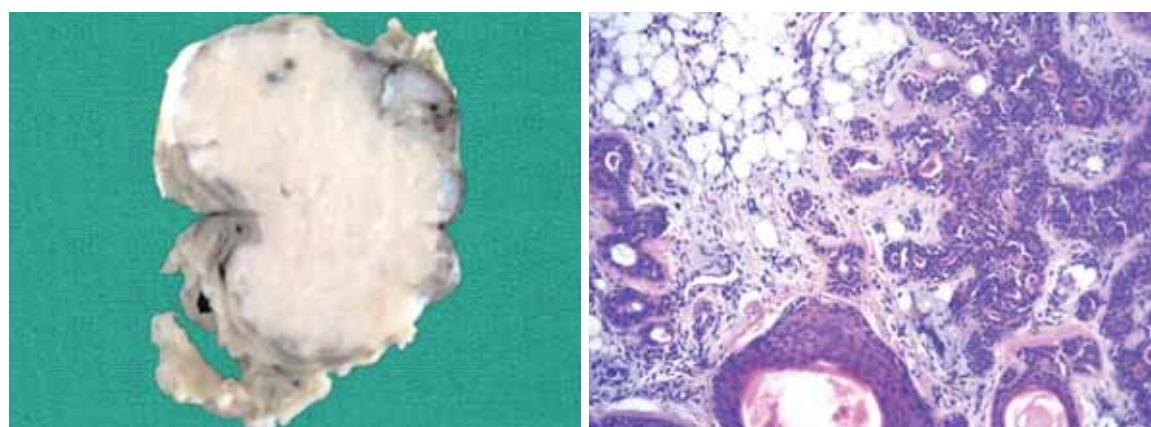


Fig. 4: Gross and microscopy of pleomorphic adenoma

dentigerous cyst. Lining revealed a white subtly wrinkled surface which is a feature of keratocyst. Correlating with clinical and gross findings, we arrived at a diagnosis of follicular keratocyst, a variant of odontogenic keratocyst which was later confirmed histologically (Fig. 2).

Case 3: Appeared macroscopically as a tumor bearing area of the jaw showing a cylindrical swelling expanding the bone and extending into extra osseous soft tissue. On section

grayish white tissue replacing the bone which is readily cut and containing no calcified tissue. Most areas were cystic with little intervening solid tissue. With the clinical history grossly we arrived at the diagnosis of ameloblastoma which was later confirmed histologically (Fig. 3).

Case 4: Appeared macroscopically as a well circumscribed soft tissue lesion and the cut surface had a variegated appearance and consistency varied in different areas. Most

of the areas were soft and mucoid, and few areas were grayish white and firm. Cystic and hemorrhagic areas were not present. With the clinical history grossly we arrived at the diagnosis of pleomorphic adenoma which was later confirmed histologically (Fig. 4).

CONCLUSION

Macroscopic features are helpful in the differential diagnosis of various cases especially those of challenge. The details of the gross specimen have to be properly examined at the initial set up so that the important details are not missed out. In case, the details are not recorded and studied in the initial stages of gross examination they cannot be obtained

later. Once sections are made and subjected for processing the specimen are unsuitable for gross examination. So a pathologist has to take adequate care not to miss out the important macroscopic detail as it is always an important clue for the final diagnosis.

REFERENCES

1. Mohan H, Mohan S. Introduction to pathology. Essential pathology for dental students. 4th ed. Jaypee Brothers Medical Publishers (P) Ltd. 2012;1-7.
2. Rosai J, Ackerman LV. Gross techniques in surgical pathology. Surgical Pathology. 9th ed. Mosby 2004;1:25-36.
3. Underwood JCE. Introduction to Pathology. General and Systemic Pathology. 4th ed. Churchill Livingstone Elsevier, 2004;3-10.