

Odontogenic Keratocyst with Atypical and Aggressive Behavior: Case Report

Rafael Martins Afonso Pereira¹, Vitor Carvalho Rodrigues², Gabriella Moreira dos Anjos³, Helvécio Marangon Jr.⁴

ABSTRACT

Introduction: The Odontogenic Keratocyst (OKC) is a potentially destructive cyst with a high probability of recurrence. This pathological lesion represents about 11% of all odontogenic cysts, being considered the third most common cyst of the jaws and with a slight predilection for the male gender.

Case presentation: Clinically, patients affected by OKC are generally asymptomatic and 80% of them remain in this form for about 2 years. The objective of this work is to report a clinical case of a 14-year-old male patient sought dental care with painful symptoms and facial asymmetry. After performing imaging tests, it was possible to observe an extensive radiolucent lesion with cortical bone expansion associated with tooth 17, displaced by the lesion. The initial hypothesis was dentigerous cyst.

Management and prognosis: The lesion was enucleated and a diagnosis of OKC was determined after histopathological evaluation. The treatment of choice was the complete enucleation of the cyst. The OKC has a high rate of recurrence and, so, it is necessary to know the various risk factors that can influence the reappearance of the injury. The method of treating OKC is a controversial subject that generates much discussion.

Conclusion: The present case demonstrates that the odontogenic keratocyst can present atypical behavior and characteristics, with the presence of bone cortical expansion, displacement of teeth, facial asymmetry and painful symptoms.

Keywords: Atypical behavior. Differential diagnosis. Odontogenic keratocyst.

Oral and Maxillofacial Pathology Journal (2020): <http://www.ompj.org/archives>.

INTRODUCTION

The Odontogenic Keratocyst (OKC) is a cyst of singular odontogenic origin, potentially destructive and with a high probability of recurrence¹. This pathological lesion represents about 11% of all odontogenic cysts^{2,3}, being considered the third most common cyst of the jaws and with a slight predilection for the male gender⁴⁻⁶. It is a consensus in the literature that the OKC originates from the dental lamina¹, but that it can also originate from the cells of the overlying epithelium⁷.

Several diseases that affect the gnathic bones have characteristics that can simulate an OKC and, therefore, it is necessary to establish them as a differential diagnosis. Traumatic bone cyst, central giant cell granuloma, odontogenic myxoma, ameloblastoma, root cyst, residual cyst and lateral periodontal cyst are some of these diseases^{8,9}. When OKC is associated with an impacted tooth, which corresponds to about 30% of cases¹⁰, the main differential diagnosis is with the Dentigerous Cyst¹¹. Thus, in order to arrive at the definitive diagnosis of OKC, it is essential to perform the histopathological examination to establish the best planning and management for the case⁹. In this clinical case, the first diagnostic hypothesis considered was that of a dentigerous cyst, mainly due to the characteristic of bone expansion associated with the impacted tooth.

CASE REPORT

Patient W.E.J.S, male, feoderma, 14 years old, sought dental care

¹⁻⁴School of Dentistry, University Center of Patos de Minas (UNI-PAM), Patos de Minas, Minas Gerais, Brazil.

Corresponding Author: Rafael Martins Afonso Pereira, School of Dentistry, University Center of Patos de Minas, Av. Marabá, 831 – Alto dos Caiçaras, Zip Code: 38703-236, Patos de Minas, MG, Brazil. E-mail: rafaelmap@unipam.edu.br, Telephone and fax: +55 (34) 3826-2500.

How to cite this article: Pereira R.M.A, Rodrigues V.C, Dos Anjos G.M, Marangon Jr. H. Odontogenic Keratocyst with Atypical and Aggressive Behavior: Case Report. Oral Maxillofac Pathol J 2020;11(2):70-73.

Source of Support: Nil

Conflict of Interest: None

with painful symptoms and asymmetry on the left side of the face (Figure 1). Imaging examinations of panoramic radiography and computed tomography were performed, revealing an extensive unilocular radiolucent lesion, with 5cm in its largest diameter, in the region of the left mandibular branch and angle, with the presence of cortical bone expansion (Figures 2 and 3). The lesion was associated with tooth 17, an included tooth, which was displaced to the posterior region of the mandible (Figure 4). Due to the patient's clinical and imaging characteristics, the initial diagnostic hypothesis was a dentigerous cyst. At the beginning of the surgi-

cal procedure, before the initial incision, an aspiration puncture was performed, which resulted in a dense, whitish-colored liquid compatible with keratin (Figure 5). After the incision and curettage, the presence of a thin, friable fibrous capsule and cystic lumen containing white solid material compatible with keratin (Figure 6) was observed. Thus, a new diagnostic hypothesis of odontogenic keratocyst was established. The lesion was fully enucleated (Figures 7 and 8), under local anesthesia, and sent for histopathological examination. Microscopic examination revealed a cystic capsule with an epithelial lining of the luminal surface composed of stratified squamous epithelium organized in 6 to 8 cell layers, with the presence of flattened, cuboidal parakeratotic epithelial cells (Figure 9). In the basal layer, the typical palisade organization of hyperchromatic epithelial cells was observed. The epithelium and the interface with underlying connective tissue

were flat. Therefore, the definitive diagnosis of odontogenic keratocyst was established for the case.

DISCUSSION

In 2005, the World Health Organization (WHO) defined OKC as a benign, intraosseous, potentially aggressive, keratocystic odontogenic tumor (KCOT), of odontogenic origin, coated with stratified parakeratinized squamous epithelium, presenting in uni or multicystic form¹². However, in 2017, WHO reclassified KCOT into OKC based on evidence of non-neoplastic clinical behavior⁴.

Clinically, patients affected by OKC are generally asymptomatic and 80% of them remain in this way for about 2 years⁶. However, when symptoms occur, pain, edema or secretion are the most frequently observed⁹. Due to the recurrent absence of symptoms, many

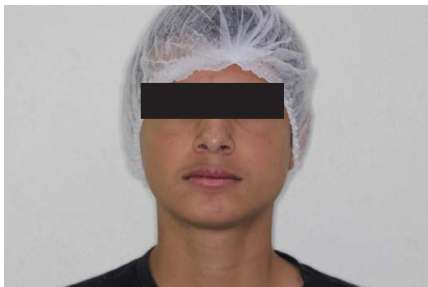

Figure 1: Patient with facial asymmetry on the left side.

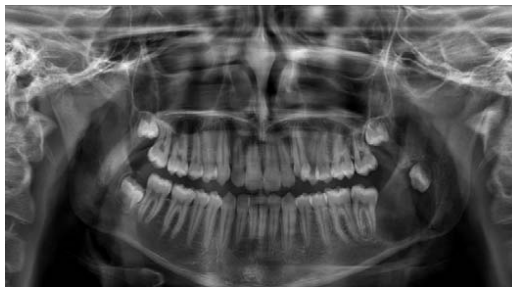

Figure 2: Panoramic radiography showing extensive radiolucent lesion.

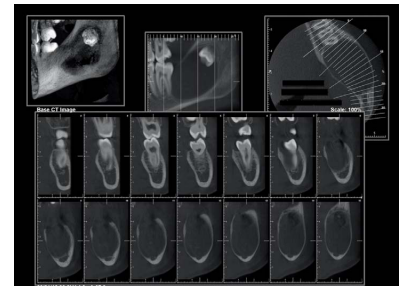


Figure 3: Computed tomography showing the presence of cortical bone expansion.

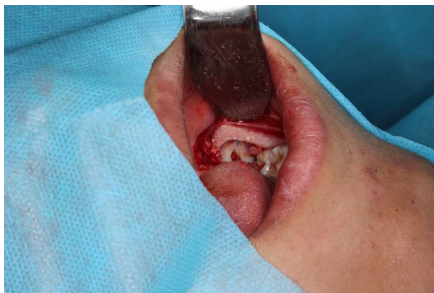

Figure 4: Displacement of tooth 17 to the posterior region of the mandible.

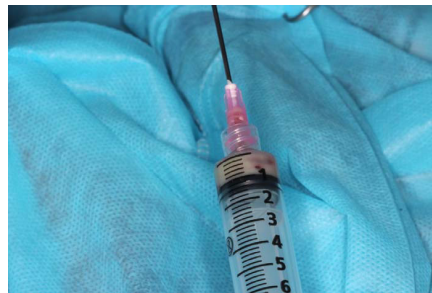

Figure 5: Dense, whitish liquid, resulting from aspiration puncture.

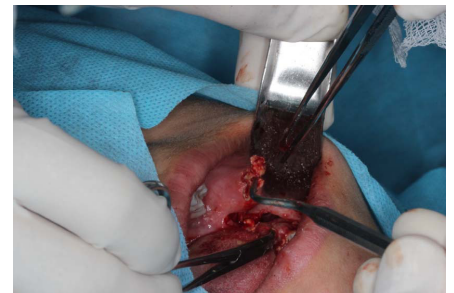

Figure 6: Curettage, with the presence of whitish solid material, compatible with keratin.

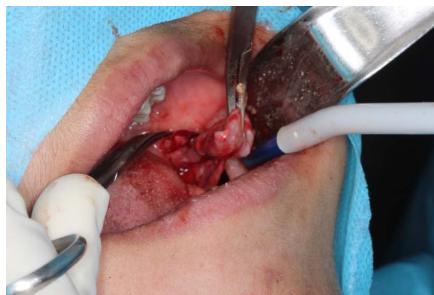


Figure 7: Enucleation of the cystic capsule.

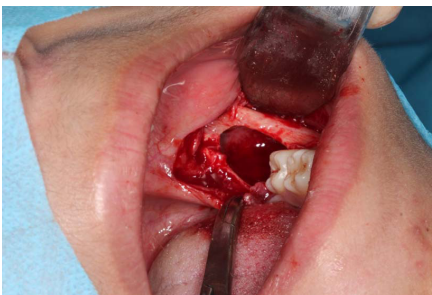


Figure 8: Completely enucleated lesion.

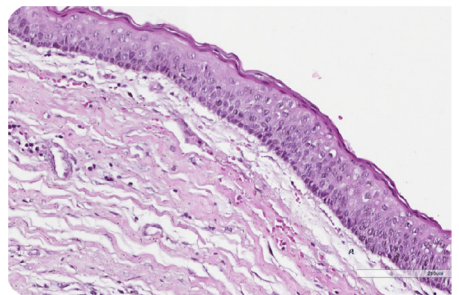


Figure 9: Microscopic slide showing a cystic capsule covered by stratified parakeratinized epithelium, with the presence of flat parakeratotic epithelial cells.

of the findings of OKC are made by means of routine dental radiographs¹³, and in the present case, the painful complaint brought by the patient was essential for establishing a rapid diagnosis. In this context, it is important to recognize the usual radiographic characteristics of OKC, being characterized by radiolucent lesions, with smooth and cortalized edges, in the unilocular (most common), or multilocular form^{11,13}. Antero-posterior intraosseous growth¹³ can also be observed with unusual or nonexistent tooth displacement¹¹. It is worth mentioning that the patient in the present case had a unilocular lesion associated with tooth 17, with atypical aggressive behavior, since it is possible to observe, through imaging tests, the expansion of the buccal and mandibular lingual bone corticals.

In about 60 to 80% of clinical cases, the mandible is the bone most affected by OKC, with the anatomical regions of the angle and branch being the most affected^{6,11}. These studies are in agreement with the results presented in a recent and important systematic review and meta-analysis, in which 21% of patients are more likely to have OKC in the posterior mandible region¹⁴. In this clinical case, the location of the OKC is in line with the world literature, however, the case becomes unusual in view of the patient's age, since the age group of 30 to 40 years is the most affected^{2,5}.

Among imaging tests, panoramic radiography is still the first option to perform an initial assessment of lesions involving gnathic bones. However, in order to obtain an image with better resolution and spatial dimensioning, with more accurate measurements and capable of showing the proximity of the lesion with adjacent anatomical structures, it is necessary to use computed tomography^{15,16}. In addition, it is through it that it is possible to better assess tooth resorption and the expansion or rupture of the bone cortex caused by OKC¹⁵.

In general, OKC treatment methods can be conservative, aggressive or radical. Marsupialization, decompression and simple enucleation fall under conservative methods of treatment, while cryosurgery, peripheral ostectomy and curettage with Carnoy's solution are within aggressive management. As a radical treatment, only bone resection is considered¹⁷.

The most appropriate treatment for OKC is still a controversial subject that generates much discussion¹⁷. Some authors defend marsupialization and decompression because they are more conservative and, consequently, preserve important anatomical structures^{5,18}. However, it is believed that the treatment of marsupialization is ineffective due to the high rate of associated recurrence, and is therefore not recommended^{2,17}. Other authors believe that treatment should be carried out in two stages, starting with marsupialization followed by enucleation^{2,19}. There are also authors who advocate only conservative enucleation²⁰, enucleation with the application of Carnoy's solution for primary OKC²¹ and decompression followed by enucleation^{9,22,23}. The only consensus in the literature refers to the radical treatment of OKC, in which minimal recurrence rates are observed, but a high rate of morbidity in patients^{2,17}. In the present case, marsupialization was initially planned followed by future enucleation. However, as it was observed in the intraoperative period that the OKC was detaching out completely and without risk of injury to the lower alveolar nerve, it was decided to perform the complete enucleation of the lesion directly.

Because the OKC has a high rate of recurrence, it is necessary

to know the various risk factors that can influence the reappearance of the injury. The probability of recurrence of OKC is twice as high when it is multilocular^{22,24} and when it affects the mandible^{13,25}. Recurrence is directly proportional to the antero-posterior dimension of the lesion and inversely proportional to the patient's age¹³. The possibility of recurrence of OKC is also directly related to the preservation of the dental element associated with the lesion, with a rate of 66.7%^{24,26}. The great variability in the OKC recurrence rates found in the literature is due to the number of patients, type of treatment and follow-up period²⁷. These factors provide different rates of recurrence found in the literature, ranging from 19.8%¹⁴ to 30%^{2,4,24,17,28}. It is known that the probability of recurrence increases in the first five years after treatment and decreases in the first 10 years after treatment^{9,26}. Based on this information, radiographic monitoring is recommended once a year, for the first 5 years, and once every 2 years thereafter^{9,29}. In this clinical case, a rigorous clinical and radiographic follow-up was recommended, since the patient is only 14 years old and has a large unilocular anteroposterior lesion in the mandible.

CONCLUSION

Contradicting the absolute majority of the world literature, this case demonstrates that the odontogenic keratocyst can present atypical behavior and characteristics, with the presence of cortical bone expansion, displacement of teeth, facial asymmetry and painful symptoms. Even with the OKC showing such aggressive biological characteristics, the treatment of choice was the complete enucleation of the cyst.

REFERENCES

1. Deshmukh, Revati Shailesh et al. Odontogenic keratocyst with granular cell changes: a distinctive finding. *Journal of oral and maxillofacial pathology: jomfp*, v. 23, n. 3, p. 432, 2019.
2. Johnson, Nigel R. Et al. Frequency of odontogenic cysts and tumors: a systematic review. *Journal of investigative and clinical dentistry*, v. 5, n. 1, p. 9-14, 2014.
3. Menon, suresh. Keratocystic odontogenic tumours: etiology, pathogenesis and treatment revisited. *Journal of maxillofacial and oral surgery*, v. 14, n. 3, p. 541-547, 2015.
4. El-Naggar, Adel k. Et al. (ed.). *Who classification of head and neck tumours*. International agency for research on cancer, 2017.
5. Sansare, Kaustubh et al. Keratocystic odontogenic tumor: systematic review with analysis of 72 additional cases from mumbai, india. *Oral surgery, oral medicine, oral pathology and oral radiology*, v. 115, n. 1, p. 128-139, 2013.
6. Schuch, Lauren Frenzel et al. A brazilian multicentre study of 2,497 isolated cases of odontogenic keratocysts. *Oral diseases*, 2020.
7. Nayak, Meghanand T. Et al. Odontogenic keratocyst: what is in the name?. *Journal of natural science, biology, and medicine*, v. 4, n. 2, p. 282, 2013.
8. Chrcanovic, b. R.; gomez, r. S. Idiopathic bone cavity of the jaws: an updated analysis of the cases reported in the literature. *International journal of oral and maxillofacial surgery*, 2019.
9. Kshirsagar, Rajesh Ashok et al. Odontogenic keratocyst: developing a protocol for surgical intervention. *Annals of maxillofacial surgery*, v. 9, n. 1, p. 152, 2019.
10. Sánchez-burgos, rocío et al. Clinical, radiological and therapeutic features of keratocystic odontogenic tumours: a study over a decade. *Journal of clinical and experimental dentistry*, v. 6, n. 3, p. E259, 2014.
11. Kitisubkanchana, jira et al. Odontogenic keratocyst and ameloblastoma: radiographic evaluation. *Oral radiology*, p. 1-11, 2020.
12. Nair, keerthi k. Et al. Keratocystic odontogenic tumor: a case report

- and review of literature. *Journal of Indian Academy of Oral Medicine and Radiology*, v. 27, n. 2, p. 253, 2015.
13. Leung, Y. Y. et al. Results of the treatment of keratocystic odontogenic tumours using enucleation and treatment of the residual bony defect with Carnoy's solution. *International Journal of Oral and Maxillofacial Surgery*, v. 45, n. 9, p. 1154-1158, 2016.
 14. Da Silva, Yuri Slusarenko; Stoelinga, Paul JW; da Graça Naclério-Homem, Maria. The presentation of odontogenic keratocysts in the jaws with an emphasis on the tooth-bearing area: a systematic review and meta-analysis. *Oral and Maxillofacial Surgery*, p. 1-15, 2019.
 15. Alves, Daniel Berretta Moreira et al. Evaluation of mandibular odontogenic keratocyst and ameloblastoma by panoramic radiograph and computed tomography. *Dentomaxillofacial Radiology*, v. 47, n. 7, p. 20170288, 2018.
 16. Macdonald, David; Angelopoulos, Christos; Scarfe, William C. Cone beam computed tomography and maxillofacial diagnosis. In: *Maxillofacial Cone Beam Computed Tomography*. Springer, Cham, 2018. P. 469-551.
 17. Kaczmarzyk, T.; Mojsa, I.; Stypulkowska, J. A systematic review of the recurrence rate for keratocystic odontogenic tumour in relation to treatment modalities. *International Journal of Oral and Maxillofacial Surgery*, v. 41, n. 6, p. 756-767, 2012.
 18. Wushou, Alimujiang; Zhao, Ya-jun; Shao, Zhi-ming. Marsupialization is the optimal treatment approach for keratocystic odontogenic tumour. *Journal of Cranio-Maxillofacial Surgery*, v. 42, n. 7, p. 1540-1544, 2014.
 19. Giuliani, Michele et al. Conservative management of a large odontogenic keratocyst: report of a case and review of the literature. *Journal of Oral and Maxillofacial Surgery*, v. 64, n. 2, p. 308-316, 2006.
 20. Vijayarangan, Sathyabama; Pandian, Vikraman Baskara. Management of the odontogenic keratocyst—six cases with conservative management supported by chemical and electrochemical cauterization. *Cureus*, v. 11, n. 11, 2019.
 21. Al-Moraissi, Essam Ahmed et al. What surgical treatment has the lowest recurrence rate following the management of keratocystic odontogenic tumor?: a large systematic review and meta-analysis. *Journal of Cranio-Maxillofacial Surgery*, v. 45, n. 1, p. 131-144, 2017.
 22. De Castro, Mayara Santos et al. Conservative surgical treatments for nonsyndromic odontogenic keratocysts: a systematic review and meta-analysis. *Clinical Oral Investigations*, v. 22, n. 5, p. 2089-2101, 2018.
 23. Polak, Kamil et al. Odontogenic keratocyst of the mandible: a case report and literature review. *Dental and Medical Problems*, 2019.
 24. Chrcanovic, Bruno Ramos; Gomez, Ricardo Santiago. Recurrence probability for keratocystic odontogenic tumors: an analysis of 6427 cases. *Journal of Cranio-Maxillofacial Surgery*, v. 45, n. 2, p. 244-251, 2017.
 25. Kinard, Brian et al. How well do we manage the odontogenic keratocyst? A multicenter study. *Oral Surgery, Oral Medicine, Oral Pathology and Oral Radiology*, v. 126, n. 5, p. E243, 2018.
 26. Fidele, Ayimi-Bushabu et al. Recurrence of odontogenic keratocysts and possible prognostic factors: review of 455 patients. *Medicina Oral, Patología Oral y Cirugía Bucal*, v. 24, n. 4, p. E491, 2019.
 27. Sigua-Rodríguez, Eder Alberto et al. Is surgical treatment based on a 1-step or 2-step protocol effective in managing the odontogenic keratocyst?. *Journal of Oral and Maxillofacial Surgery*, v. 77, n. 6, p. 1210. E1-1210. E7, 2019.
 28. Antonoglou, Georgios A. et al. Non-syndromic and syndromic keratocystic odontogenic tumors: systematic review and meta-analysis of recurrences. *Journal of Cranio-Maxillofacial Surgery*, v. 42, n. 7, p. E364-e371, 2014.
 29. Borghesi, Andrea et al. Odontogenic keratocyst: imaging features of a benign lesion with an aggressive behaviour. *Insights into Imaging*, v. 9, n. 5, p. 883-897, 2018.